



Systematic Review



Diagnostic Modalities in Oral Pathology: Integrating Advance Diagnostic Techniques to Differentiate Malignant and Benign Lesions

Kanza Iqbal¹, Kanwal Fatima², Madeeha Minhas³, Aman Ullah Siddiqui⁴, Bisma Khizer⁴, Muhammad Anique⁵ and Muhammad Arsalan Shah⁶

¹Department of Operative Dentistry and Endodontics, Institute of Dentistry, Combined Military Hospital, Lahore Medical College, Lahore, Pakistan

²Department of Oral Pathology, Liaquat University of Medical and Health Sciences, Jamshoro, Pakistan

³Department of Basic Sciences, College of Science and Health Professions, King Saud bin Abdulaziz University for Health Sciences, Jeddah, Saudi Arabia

⁴Department of Biology, Bhitai Dental and Medical College, Mirpurkhas, Pakistan

⁵Department of Pathology, Bhitai Dental and Medical College, Mirpurkhas, Pakistan

⁶Department of Pathology, Allied Health Sciences Academy, Lahore, Pakistan

ARTICLE INFO

Keywords:

Oral Pathology, Malignant Lesions, Histopathology, Cone-Beam Computed Tomography

How to Cite:

Iqbal, K., Fatima, K., Minhas, M., Siddiqui, A. U., Khizer, B., Anique, M., & Shah, M. A. (2024). Diagnostic Modalities in Oral Pathology: Integrating Advance Diagnostic Techniques to Differentiate Malignant and Benign Lesions: Integrating Advanced Diagnostic Techniques to Malignant and Benign Lesions. *Pakistan Journal of Health Sciences*, 5(12), 331-338. <https://doi.org/10.54393/pjhs.v5i12.2535>

*Corresponding Author:

Muhammad Arsalan Shah
Department of Pathology, Allied Health Sciences Academy, Lahore, Pakistan
muhammadarsalanshahpath01@gmail.com

Received Date: 10th November, 2024

Acceptance Date: 27th December, 2024

Published Date: 31st December, 2024

ABSTRACT

Diagnosis and treatment planning in oral pathology is dependent on the differentiation of malignant from benign oral lesions. Clinical, radiographic and histopathological methods combined provide comprehensive diagnosis and patient care property. **Objectives:** To describe how the combined use of clinical assessments, imaging modalities and histopathological techniques can be used together to improve the differentiation of oral lesions between malignant and benign pathologies. **Methods:** In this paper, a systematic review was conducted using PRISMA guidelines. Studies published between January 2013 and April 2024 were searched from databases including PubMed, Google Scholar and Semantic Scholar. After the screening, 51 met the inclusion criteria from a total of 112 articles initially screened. Sixteen studies were ultimately analysed that examined oral pathology diagnostic advancements utilizing a combination of clinical, radiographic, and histo-chemo-pathological approaches. **Results:** Combining clinical examinations with imaging techniques such as cone beam computed tomography, and histopathological evaluations increases the accuracy of oral lesion diagnosis. The integrated approaches reveal malignancies earlier and reduce misdiagnoses. Histopathological analysis was shown to be the gold standard, but even this can be improved with additional clinical and radiographic data. **Conclusions:** It was concluded that accurate diagnosis and differentiation of benign vs. malign oral lesions requires the integration of clinical, radiographic, and histopathological methods. Such a multi-modal approach will support early detection and consequent tailored treatment strategies that maximise the patient outcome.

INTRODUCTION

Oral lesions are difficult to diagnose properly due to their various presentations and similarities in morphological states when each state is distinct in terms of severity. Oral cancers are a major global health priority with a high incidence throughout certain regions, i.e., South Asia. Prevalence is further influenced by tobacco, areca nut and alcohol usage as risk factors, which are common in India, Pakistan and Sri Lanka [1, 2]. The burden of oral cancer

makes it evident that diagnostic tools are required to differentiate between benign and malignant lesions at early stages with accuracy. Timely differentiation between benign and malignant lesions is critical for optimized and result oriented treatment [3]. This review will talk about diagnostic techniques which can make accurate early diagnostic and differentiation dreams come true. Moving forward, the current diagnostic practices are vastly based

on clinical examination with histopathological analysis. Histopathology is regarded as the gold standard in pathological confirmation because it identifies abnormalities at a cellular level. It requires specialized laboratory resources and expertise for correct identification of tumor via this technique [4]. Similarly, cone beam computed tomography (CBCT) has been shown to emerge as a significant imaging technique. CBCT provides three-dimensional high-resolution imaging of the whole maxillofacial region with small percentage distortion, allowing detailed visualization of size, shape, and involvement of bone in lesions. It is another particularly useful modality for assessing bone-invasive lesions, which are a frequent sign of advanced malignancy [5]. Differentiating lesion types is also highly promising with another related imaging modality, multiphase computed tomography (MCT) [6]. Optical coherence tomography (OCT) is noninvasive and its strength lies in providing high-resolution images of epithelial and sub-epithelial structures for the detection of malignant changes in oral tissues. Specific stains, like periodic Acid-Schiff (PAS) and Alcian blue, have been shown to enhance diagnostic clarity for specific lesion types as the tissue characteristics associated with more aggressive lesions stand out more clearly. These stains are also used by pathologists to assess hyalinization in oral sub-mucous fibrosis and fibrosis severity in salivary gland tumors, correlating those features with disease severity and recurrence risk [7]. Immunohistochemically markers such as Cluster of Differentiation 34 (CD34), and alpha-smooth muscle actin (α -SMA) are regularly used to determine tumor behaviour in oral squamous cell carcinoma (OSCC) and can give vital information regarding aggressiveness and guide more precise treatment planning [8]. Even if present interventions help in diagnosis there is a continuous need for improvement in accuracy. Often the clinical examination is insufficient since benign and malignant lesions can share similar morphological patterns, potentially resulting in misdiagnoses [4]. Biopsies required for histopathological analysis are uncomfortable, and invasive and may not be feasible for everyone despite it being considered as a standardized treatment. [9]. Cone-beam computer tomography (CBCT) and optical coherence tomography (OCT) show accurate diagnostic results but their standalone application is not enough with advancing day and age. CBCT focuses on bony involvement while OCT lags in diagnostic accuracy when used alone. High-cost imaging and staining techniques make them limited to be used by resourceful healthcare systems only [10]. Overall any technique when used in isolation is insufficient and thus requires to be used in combination to enhance accuracy. Moreover, studies demonstrate how incorporating advanced imaging enables the integration of

histopathological analysis, but there is a clear need to develop comprehensive frameworks that bring together such modalities. In particular, many current studies are confined to isolated populations in high-prevalence areas, and little research has been done on the adaptability and efficacy of these integrated strategies across a variety of demographic and geographic settings. To overcome these limitations research has also been conducted in recent decades in which the technique has been developed to employ the power of the clinical method, radiographic technique and histopathological method together to provide high diagnostic accuracy. When teamed with artificial intelligence algorithms, such as artificial neural networks (ANN) and support vector machines, OCT has been shown to have an over 90 percent sensitivity for identifying early-stage malignancies. In settings where biopsy is difficult or limited, the ability to confirm the immune phenotype without requiring a biopsy is especially valuable [10, 11]. But still, there is a need to integrate these studies to get a better picture of the current situation of interventions for oral lesions.

This study aims to bridge current gaps in the literature by evaluating the combined efficacy of these techniques in multiple populations (for generalizability) and diagnostic challenges. This study synthesizes and reviews findings for multimodal diagnostic approaches and makes a case in favor of an integrative framework that combines advancing clinical assessment, advanced imaging methodologies and refined histopathologic techniques. Importantly, such an integrated diagnostic strategy not only improves accuracy but also has the potential to adapt to resource-rich as well as resource-limited healthcare settings.

METHODS

A systematic review was conducted as per the PRISMA guidelines between February 2024 to May 2024 to see the advancements made in differential diagnostic approaches of different oral lesions with benign and malignant predispositions. The transparency and rigour of the review process included two independent reviewers scouring databases central to oral pathology and diagnostic innovation, namely, PubMed, Google Scholar, and Semantic Scholar. In selecting these databases, the study looked for databases that had full coverage of published clinical, radiographic and histopathological research that could be pertinent to oral lesions. 70% of articles were taken from PubMed, 20% from Google Scholar and 10% from Semantic Scholar. The studies in the literature search were restricted to those between January 2013 to April 2024, using keywords such as "diagnostic techniques in oral lesions," "clinical differentiation of oral malignancies," "histopathology and oral lesions" and "radiographic imaging in oral diagnosis." Initially, 112 studies were identified. Reviewers screened the studies independently and

selected studies to minimize bias and ensure relevance. Inclusion criteria demanded studies must contain articles which were based on multimodal approaches to diagnose oral lesions, must be within the last five years if included in a table and must contain complete data i.e. sample size, population, reliable intervention etc. Older studies, studies with incomplete data, studies with just abstract and title and studies with irrelevant data were excluded. After eliminating 10 duplicates, 102 studies were subject to preliminary screening. After screening 51 studies by title and abstract, these studies were excluded according to their evaluation as not relevant to oral lesion diagnosis, lack of comprehensiveness of methodology, or not fitting in the included criteria. Of the remaining 51 studies, all of which were focused on integrated diagnostic techniques, just 16 were selected based on the completion of data. To achieve quality filtering in this systematic review several statistical methods were used to test study quality and to keep the results trustworthy. Predefined quality assessment tools such as the Newcastle-Ottawa Scale (NOS) for observational studies, which grades studies according to selection, comparability and the assessment of the outcome, were used to evaluate each study. Cochrane Risk of Bias Tool was used for examining domains such as random sequence generation, allocation concealment, blinding, and selective outcome reporting in the cases of randomized controlled trials (RCTs). Furthermore, funnel plots and Egger's test were used to test for publication bias and asymmetries to test for study reporting bias. Heterogeneity was quantified across studies using the I^2 statistic as values greater than 50% indicate substantial heterogeneity and addressed this with random effects models. To strengthen the reliability of our conclusions regarding the diagnostic efficacy of integrated approaches for oral lesions, only high-quality (with low bias) studies were used to generate these methods ensuring that the contribution to the final analysis only came from high-quality studies with minimal bias. From each study, data were extracted including authorship, publication year, geographic focus, study design, diagnostic methodology and clinical outcome. The collection of studies included in this systematic analysis spanned a variety of regions including Asia, Europe, and the USA and included diagnostic advances in a variety of lesion types and populations. The findings confirmed the effectiveness of integrating clinical evaluations, imaging modalities such as cone beam computed tomography (CBCT) and histopathological methods for differential diagnosis of benign and malignant lesions, indicating that an integrative diagnostic approach leads to an improvement in early detection and treatment planning for oral pathologies. The application of the PRISMA method in the process of selecting the studies additionally subdivides the process into stages, such as identification, screening, quality assessment, and inclusion. From records recognized, 112 were considered, but eliminating duplicates made the

number to 102 screened, of which 51 were considered for the study due to their diagnostic value. Of the 41 studies identified full literature review, only 16 satisfied all the inclusion criteria and were included in the final analysis, addressing the diagnostic applications of multimodal diagnostic techniques for oral lesions with malignant potential (Figure 1).

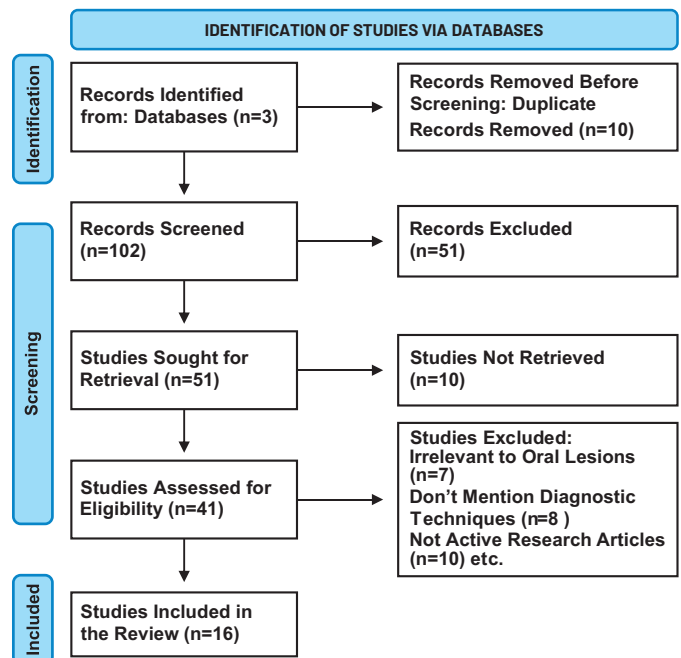


Figure 1: Studies Selection according to PRISMA guidelines

RESULTS

This systematic review by following PRISMA guidelines is based on 16 studies of the combined effectiveness of clinical, radiographic and histopathological techniques in differentiating benign from malignant oral lesions. The study was reviewed from various databases, with 65% percent of the studies taken from PubMed and 35% percent from Google Scholar and Semantic Scholar. The selected studies considered the diagnostic precision along with accuracy in early detection, as well as the application of specific modalities in oral pathology. To capture a comprehensive understanding of diagnostic advancements, the study designs included a mix of methodologies: Nine retrospective analyses, four prospective studies, and three observational studies on the synergistic effect of these diagnostic modalities. The role of advanced imaging techniques such as cone-beam computed tomography (CBCT) and multiphase CT with machine learning for improving clinical and histopathological evaluations was emphasized in all the studies. It was found that combining multiple diagnostic techniques improves accuracy, sensitivity and specificity to a great degree. For example, such studies that combine cone beam computed tomography (CBCT) with clinical examination showed accuracy increases as high as 25%.

OCT, in conjunction with AI-based algorithms, had over 90% sensitivity to identify early malignancy, and radio-mic models showed high diagnostic accuracy with the area under the curve (AUC) of 0.84 to 0.94 across the study. Further, when using hybrid AI models linking convolutional neural networks (CNN) with support vector machines (SVM), the diagnostic accuracies in certain lesion types reached over 99%. By underlining the superior diagnostic power of multimodal approaches, particularly when combined with advanced imaging and machine learning, these findings reinforce the need for clinicians to avoid an approach that neglects the combination of these two clinical capabilities. Hence these findings suggest the use of a multimodal diagnostic approach to the assessment of oral lesions. The accumulated evidence indicates that the incorporation of advanced imaging into clinical and histopathological assessment might soon become standard practice, leading to greater diagnostic precision and improved patient outcomes, particularly for early malignancy detection (Table 1).

Table 1: Studies on Diagnostic Approaches in Oral Pathology

Reference	Study Designs	Sample Size	Diagnostic Techniques	Key Findings	Conclusions
Nadeem et al., [12]	Retrospective observational	90	Histopathology, special stains (PAS, Alcian blue, Safranin O, Picrosirius red)	Differential stains helped assess hyalinization severity and potential aggressiveness in oral lesions, showing significant correlations with disease severity in some cases	SOH and specific stains can help predict aggressiveness and recurrence potential in salivary gland tumours and fibrosis severity in OSMF
Sindhi et al., [13]	Retrospective, cross-sectional	858	Clinical and histopathological comparison	Agreement between clinical and histopathological diagnoses was only 44.1%, with the highest agreement for odontogenic tumours and varying by lesion location	Histopathological confirmation is crucial for accurate diagnosis of oral lesions, especially for complex cases, underscoring the importance of biopsy
James et al., [14]	Validation study	232 patients, 347 lesions	Optical Coherence Tomography (OCT) combined with ANN and SVM algorithms	OCT with AI yielded >90% sensitivity for oral cancer screening; high accuracy in distinguishing benign, dysplastic, and malignant lesions	OCT with automated algorithms is effective as a portable, low-cost diagnostic tool for resource-limited settings
Fati et al., [15]	Observational study	5192 images	Hybrid AI methods combining CNN, SVM, and ANN with feature extraction (e.g., LBP, DWT)	Hybrid AI methods achieved 99.1% accuracy in OSCC detection based on histopathological images; effective in feature extraction and classification	Hybrid methods using CNN, SVM, and feature extraction are promising for early OSCC diagnosis through histological images
Verma et al., [16]	Cross-sectional observational study	100	Histopathological analysis of biopsies	High prevalence of well-differentiated squamous cell carcinoma (47%), with a male predominance (76%) linked to lifestyle factors like tobacco use	Emphasizes the importance of histopathological examination and early diagnosis in improving outcomes for oral lesions and cancer
Yu et al., [17]	Retrospective study	312	Multiphasic CT-based radiomics with machine learning	LASSO-SVM model with three-phase CT radio-mics showed the highest AUC (0.936) in differentiating benign from malignant tumours.	Multiphasic CT-based radiomics combined with machine learning can effectively distinguish between benign and malignant parotid tumours.
Orikpete et al., [18]	Retrospective histopathologic study over 10 years	574 biopsies	Histopathologic examination and lesion categorization	Non-neoplastic lesions (68.5%) were more common, with pyogenic granuloma as the most frequent; benign lesions outnumbered malignant ones.	Histologic examination is critical for accurate diagnosis of gingival lesions due to the high frequency of non-neoplastic lesions.
Maqsood et al., [19]	Cross-sectional study	80	Histological and immunohistochemical analysis using Cd34 and α -SMA markers	CD34 expression is significantly associated with OSCC histological grading; high α -SMA in poorly differentiated OSCC indicates aggressive behaviour.	CD34 and α -SMA are valuable in diagnosing OSCC and assessing tumour aggression, with prognostic significance in OSCC differentiation.
Czerninski et al., [20]	Observational study	133	Clinical image evaluation	Half of the benign images were evaluated correctly; clinicians performed better than students, with diagnostic accuracy increasing by clinical experience and education level.	Emphasizing visual diagnostic parameters of malignancy is valuable for improving diagnostic accuracy, especially in telehealth settings.

Zheng et al., [21]	Retrospective cohort study	388	CT-based radio-mics analysis	The SVM model showed the highest predictive efficiency with an AUC of 0.844 (training) and 0.840 (test). The combined model of radio mics and clinical features had the highest accuracy.	The combined radio-mics and clinical model is effective for distinguishing benign from malignant parotid tumours and enhances clinical decision-making.
Yu et al., [22]	Multicentre retrospective	573	Deep learning on contrast-enhanced CT	Mobile Net V3 model showed the best performance with AUC improvement in radiologists' diagnostic accuracy, particularly assisting less experienced radiologists.	Deep learning models assist radiologists in distinguishing benign from malignant parotid tumours, enhancing diagnostic performance and supporting clinical decisions.
Sircan et al., [23]	Pilot Study	47	Elastic Light Single-Scattering Spectroscopy (ELSSS)	ELSSS identified malignant lesions by negative spectral slopes, achieving 80% sensitivity and 94% specificity.	ELSSS shows potential as a non-invasive screening tool for oral lesions, potentially reducing unnecessary biopsies.
Obade et al., [24]	Observational Study	44	Optical Coherence Tomography (OCT)	OCT detected structural differences in the keratin layer, epithelial layer, and basement membrane. A breached basement membrane in OSCC strongly indicated malignancy.	OCT is a non-invasive tool useful for differentiating benign and malignant oral lesions, especially through basement membrane analysis.
Xiang et al., [25]	Retrospective Study	117	Dynamic Contrast-Enhanced MRI (DCE-MRI) with Histogram Analysis	TTP and MRE parameters successfully differentiated benign from malignant parotid tumours. Entropy and kurtosis were independent predictors of malignancy.	DCE-MRI histogram parameters, particularly entropy and kurtosis, are effective in identifying and classifying parotid tumours and distinguishing benign from malignant cases.
Takumi et al., [26]	Retrospective study	42	Multi-parametric non-contrast MR imaging (ADC, TBF, APTSI)	APTSI was significantly higher in malignant lesions; combining ADC, TBF, and APTSI improved diagnostic accuracy.	Combining ADC, TBF, and APTSI is effective in differentiating malignant from benign salivary gland lesions.
Sripodok et al., [27]	Retrospective cohort; decision tree model development	946 LGES of 14,487 biopsies	Decision tree model based on clinical characteristics (size, consistency, colour, age, duration)	Size, consistency, and duration were significant predictors of malignancy; malignant LGES had lower diagnostic concordance than non-malignant LGES.	The decision tree model aids in clinical differentiation between malignant and non-malignant LGES.

DISCUSSION

This systematic review evaluated the effectiveness of combining clinical, radiographic and histopathological techniques along with the integration of AI techniques for diagnosing oral lesions. The primary goal was to assess how combination therapies and multimodal approaches improve the ability to discriminate between benign and malignant lesions, enhance accuracy and inform clinical decision-making. The findings not only support the use of integrated diagnostic techniques but also highlight their limitations in their universality, accessibility, and application in vast clinical settings. Several imaging advances have been identified as a promise in improving early diagnosis, especially in areas with limited histopathological resources. CBCT provides high-resolution, 3D imaging of the entire maxillofacial region and makes a detailed assessment of a lesion possible, including size, shape and bone involvement. Studies demonstrated its efficacy in identifying the invasiveness of lesions to

bone with potential applications in early diagnosis of malignant cases [28, 29]. When combined with radio-mics and machine learning models, multiphasic computed tomography (CT) demonstrated high diagnostic accuracy, achieving over 90% specificity in certain lesion types. Support Vector Machines (SVM) and logistic regression models enhanced the distinction between malignant and benign tumors [30, 31]. In addition to CBCT and multiphasic CT, optical coherence tomography (OCT) offered non-invasive high-resolution imaging of epithelial and sub-epithelial structures. When it is combined with AI algorithms such as convolutional neural networks (CNNs), OCT achieves a sensitivity accuracy of up to 85% in diagnosing early tumors, especially in resource-limited settings [32, 33]. Furthermore, special stains periodic Acid-Schiff (PAS) and Alcian blue have been shown to improve diagnostic clarity by highlighting tissue properties associated with aggressive tumors. These methods

improved the assessment of fibrosis and hyalinization which is associated with the severity of the disease and its recurrence risk [34, 35]. Immunochemical markers like CD34 and α -SMA were found to be valuable for evaluating tumor aggressiveness and guiding treatment planning in oral squamous cell carcinoma (OSCC) [19, 36]. In emerging techniques, Elastic Light Single Scattering Spectroscopy (ELSSS) showed promise as a non-invasive diagnostic method. It achieved a sensitivity of up to 80% and specificity of up to 94% in distinguishing between the two types of tumors as mentioned in the text through incorporating a special type of analysis. ELSSS has shown its potential to play a central role in oral lesion screening programs, especially under conditions when biopsy procedures are not available [37, 38]. This review supports the advantages of a multimodal approach for diagnosis as they proved to serve diagnostic precision for complex and advanced tumors. Imaging techniques like CBCT and radiomics are highly for elaborated anatomical analysis [39]. AI-based techniques enhance diagnostic accuracy in low-resource settings [40]. There are some limitations to these techniques along with their advantages such as high-resolution imaging techniques are customized for resourceful settings and require expensive equipment for working that can't be applied in regions of low income. Clinical and histopathological analysis use biopsies which are invasive and harmful and not suitable for everyone. Similarly, there are also limitations and gaps to this systematic review which are discussed as follows; Some studies were focused on specific populations or geographic regions, in which case their findings may not be generalizable. These studies were confined to high prevalence regions only therefore can't advocate for broader populations. Additionally, due to differences in imaging protocols, AI algorithms and histopathological standards across studies create heterogeneity in results and, therefore less comparable. The findings emphasize the potential of multimodal diagnostic strategies to enhance clinical results. CBCT and radio mics can be clinically implemented by providing precision lesion characterization, while OCT and ELSSS offer a non-invasive alternative to biopsies. Focus is needed on standardizing protocols across all clinical platforms by integration of clinical, imaging and histopathological methods to reduce variability and biasedness. Multicenter studies will benefit in coverage of larger demographic regions and will ensure global applicability.

CONCLUSIONS

It was concluded that overall, clinical, radiographic and histopathological integration is shown to substantially increase the diagnostic accuracy of lesions of the oral mucosa, facilitating earlier detection and improved

patient outcomes. However, these findings are limited by restricted generalizability, as advanced imaging and AI-based techniques are limited to resource-rich settings, leaving underserved regions with low access. Future research should address these barriers by validating cost-effective mobile-based diagnostic tools based on cloud computing to reach further. Standardization should be introduced for globalized applicability i.e. combination of clinical, imaging and histopathological techniques. This integration will also aid in clinical practices by filling the drawbacks of each technique. Policymakers should prioritize funding for such projects. Furthermore, constructing lightweight AI protocols can enhance diagnostic consistency and reduce observer bias to extend their use throughout a variety of healthcare environments.

Authors Contribution

Conceptualization: KI, KF, MM

Methodology: KI, KF, MM, AUS, BK, MA, MAS

Formal analysis: KI, KF, MM

Writing review and editing: AUS, BK, MA, MAS

All authors have read and agreed to the published version of the manuscript

Conflicts of Interest

All the authors declare no conflict of interest.

Source of Funding

The author received no financial support for the research, authorship and/or publication of this article.

REFERENCES

- [1] Binmadi NO, Alhindi AA, Alsharif MT, Jamal BT, Mair YH. The value of a specialized second-opinion pathological diagnosis for oral and maxillofacial lesions. *BMC Oral Health*. 2023 Jun 9;23(1):378. doi:10.1186/s12903-023-03085-w
- [2] Abati S, Sandri GF, Finotello L, Polizzi E. Differential diagnosis of pigmented lesions in the oral mucosa: A clinical based overview and narrative review. *Cancers*. 2024 Jul 8;16(13):2487. doi:10.3390/cancers16132487
- [3] Parakh MK, Ulaganambi S, Ashifa N, Premkumar R, Jain AL. Oral potentially malignant disorders: clinical diagnosis and current screening aids: a narrative review. *European Journal of Cancer Prevention*. 2020 Jan 1;29(1):65-72. doi: 10.1097/CEJ.00000000000000510
- [4] Walsh T, Macey R, Kerr AR, Lingen MW, Ogden GR, Warnakulasuriya S. Diagnostic tests for oral cancer and potentially malignant disorders in patients presenting with clinically evident lesions. *Cochrane Database of Systematic Reviews*. 2021(7). doi: 10.1002

- 2/14651858.CD010276.pub3
- [5] Buenahora MR, Peraza-L A, Díaz-Báez D, Bustillo J, Santacruz I, Trujillo TG, Lafaurie GI, Chambrone L. Diagnostic accuracy of clinical visualization and light-based tests in precancerous and cancerous lesions of the oral cavity and oropharynx: a systematic review and meta-analysis. *Clinical Oral Investigations*. 2021 Jun;25:4145-59. doi: 10.1007/s00784-021-03825-7
- [6] Chen F, Ge Y, Li S, Liu M, Wu J, Liu Y. Enhanced CT-based texture analysis and radiomics score for differentiation of pleomorphic adenoma, basal cell adenoma, and Warthin tumor of the parotid gland. *Dentomaxillofacial Radiology*. 2023 Jan 1;52(2):20220009. doi: 10.1259/dmfr.20220009
- [7] Piludu F, Marzi S, Ravanelli M, Pellini R, Covello R, Terrenato I, Farina D, Campora R, Ferrazzoli V, Vidiri A. MRI-based radiomics to differentiate between benign and malignant parotid tumors with external validation. *Frontiers in Oncology*. 2021 Apr 27;11:656918. doi: 10.3389/fonc.2021.656918
- [8] Kavyashree C, Vimala HS, Shreyas J. A systematic review of artificial intelligence techniques for oral cancer detection. *Healthcare Analytics*. 2024 Jan 22:100304. doi: 10.1016/j.health.2024.100304
- [9] Jerjes W, Stevenson H, Ramsay D, Hamdoon Z. Enhancing Oral Cancer Detection: A Systematic Review of the Diagnostic Accuracy and Future Integration of Optical Coherence Tomography with Artificial Intelligence. *Journal of Clinical Medicine*. 2024 Sep 29;13(19):5822. doi: 10.3390/jcm13195822
- [10] Dilsiz A, Gül SN. Investigation of Biopsied Non-Plaque-Induced Gingival Lesions in a Turkish Population: A 5-Year Retrospective Study. *The Eurasian Journal of Medicine*. 2023 Jun;55(2):100. doi: 10.5152/eurasianjmed.2023.22063
- [11] Alessandrini L, Astolfi L, Dalloiso A, Sbaraglia M, Mondello T, Zanoletti E, Franz L, Marioni G. Diagnostic, prognostic, and therapeutic role for angiogenesis markers in head and neck squamous cell carcinoma: a narrative review. *International Journal of Molecular Sciences*. 2023 Jun 27;24(13):10733. doi: 10.3390/ijms241310733
- [12] Nadeem AM, Nagaraj B, Jagadish DA, Shetty D, Lakshminarayana S, Augustine D, Rao RS. A histopathology-based assessment of biological behavior in oral hyalinizing extraosseous lesions by differential stains. *The Journal of Contemporary Dental Practice*. 2021 Sep 28;22(7):812-28. doi: 10.5005/jp-journals-10024-3131
- [13] Sindi AM, Aljohani K. Agreement Between Clinical and Histopathological Diagnoses of Oral and Maxillofacial Lesions and Influencing Factors: A Five-Year Retrospective Study. *Clinical, Cosmetic and Investigational Dentistry*. 2024 Dec 31:273-82. doi: 10.2147/CCIDE.S473583
- [14] James BL, Sunny SP, Heidari AE, Ramanjinappa RD, Lam T, Tran AV, Kankanala S, Sil S, Tiwari V, Patrick S, Pillai V. Validation of a point-of-care optical coherence tomography device with machine learning algorithm for detection of oral potentially malignant and malignant lesions. *Cancers*. 2021 Jul 17;13(14):3583. doi: 10.3390/cancers13143583
- [15] Fati SM, Senan EM, Javed Y. Early diagnosis of oral squamous cell carcinoma based on histopathological images using deep and hybrid learning approaches. *Diagnostics*. 2022 Aug 5;12(8):1899. doi: 10.3390/diagnostics12081899
- [16] Verma S, Singh M, Kala C. Histopathological spectrum of oral cavity lesions: An observational study. *International Medicine*. 2024 Aug 22;10(2). doi: 10.91/93
- [17] Yu Q, Wang A, Gu J, Li Q, Ning Y, Peng J, Lv F, Zhang X. Multiphasic CT-based radiomics analysis for the differentiation of benign and malignant parotid tumors. *Frontiers in Oncology*. 2022 Jun 30;12:913898. doi: 10.3389/fonc.2022.913898
- [18] Orikpete EV, Iyogun CA. Histopathologic Analysis of Gingival Lesions: A 10-Year Retrospective Study. *Oral Health and Dental Science*. 2021;5(1):1-5. doi: Not available.
- [19] Maqsood A, Ali A, Zaffar Z, Mokeem S, Mokeem SS, Ahmed N, Al-Hamoudi N, Vohra F, Javed F, Abduljabbar T. Expression of CD34 and α -SMA markers in oral squamous cell carcinoma differentiation: A histological and histo-chemical study. *International Journal of Environmental Research and Public Health*. 2021 Jan;18(1):192. doi: 10.3390/ijerph18010192
- [20] Czerninski R, Mordekovich N, Basile J. Factors important in the correct evaluation of oral high-risk lesions during the telehealth era. *Journal of Oral Pathology & Medicine*. 2022 Sep;51(8):747-54. DOI: 10.1111/jop.13268
- [21] Zheng Y, Zhou D, Liu H, Wen M. CT-based radiomics analysis of different machine learning models for differentiating benign and malignant parotid tumors. *European Radiology*. 2022 Oct;32(10):6953-64. DOI: 10.1007/s00330-022-08648-4
- [22] Yu Q, Ning Y, Wang A, Li S, Gu J, Li Q, Chen X, Lv F, Zhang X, Yue Q, Peng J. Deep learning-assisted diagnosis of benign and malignant parotid tumors based on contrast-enhanced CT: a multicenter study. *European Radiology*. 2023 Sep;33(9):6054-65.

- DOI: 10.1007/s00330-023-09658-2
- [23] Sircan-Kucuksayan A, Yaprak N, Derin AT, Ozbudak İH, Turhan M, Canpolat M. Noninvasive assessment of oral lesions using elastic light single-scattering spectroscopy: a pilot study. *European Archives of Oto-Rhino-Laryngology*. 2020 May;277:1467-72. DOI: 10.1007/s00405-019-05778-1
- [24] Obade AY, Pandarathodiyil AK, Oo AL, Warnakulasuriya S, Ramanathan A. Application of optical coherence tomography to study the structural features of oral mucosa in biopsy tissues of oral dysplasia and carcinomas. *Clinical Oral Investigations*. 2021 Sep;25:5411-9. DOI: 10.1007/s00784-021-03781-4
- [25] Xiang S, Ren J, Xia Z, Yuan Y, Tao X. Histogram analysis of dynamic contrast-enhanced magnetic resonance imaging in the differential diagnosis of parotid tumors. *BMC Medical Imaging*. 2021 Dec;21:1-8. DOI: 10.1186/s12880-021-00613-1
- [26] Takumi K, Nagano H, Kikuno H, Kumagae Y, Fukukura Y, Yoshiura T. Differentiating malignant from benign salivary gland lesions: a multiparametric non-contrast MR imaging approach. *Scientific Reports*. 2021 Feb 2;11(1):2780. DOI: 10.1038/s41598-021-82291-0
- [27] Sripodok P, Laphthanasupkul P, Arayapisit T, Kitkumthorn N, Srimaneekarn N, Neeranadpuree V, Amornwatcharapong W, Hempornwisarn S, Amornwikaikul S, Rungraungrayabkul D. Development of a decision tree model for predicting the malignancy of localized gingival enlargements based on clinical characteristics. *Scientific Reports*. 2024 Sep 27;14(1):22185. DOI: 10.1038/s41598-024-29917-7
- [28] Kim CG, Lee GW, Kim HS, Han SY, Han D, Park HM. Case report: Ghost cell odontogenic carcinoma in a dog: diagnostics and surgical outcome. *Frontiers in Veterinary Science*. 2023 Oct 19;10:1267222. DOI: 10.3389/fvets.2023.1267222
- [29] Mao WY, Lei J, Lim LZ, Gao Y, Tyndall DA, Fu K. Comparison of radiographical characteristics and diagnostic accuracy of intraosseous jaw lesions on panoramic radiographs and CBCT. *Dentomaxillofacial Radiology*. 2021 Feb 1;50(2):20200165. DOI: 10.1259/dmfr.20200165
- [30] He Y, Zheng B, Peng W, Chen Y, Yu L, Huang W, Qin G. An ultrasound-based ensemble machine learning model for the preoperative classification of pleomorphic adenoma and Warthin tumor in the parotid gland. *European Radiology*. 2024 Apr 3:1-5. DOI: 10.1007/s00330-024-08975-3
- [31] Hung KF, Ai QY, Wong LM, Yeung AW, Li DT, Leung YY. Current applications of deep learning and radiomics on CT and CBCT for maxillofacial diseases. *Diagnostics*. 2022 Dec 29;13(1):110. DOI: 10.3390/diagnostics13010110
- [32] Kim DH, Kim SW, Hwang SH. Efficacy of optical coherence tomography in the diagnosing of oral cancerous lesion: systematic review and meta-analysis. *Head & Neck*. 2023 Feb;45(2):473-81. DOI: 10.1002/hed.27227
- [33] Photiou C, Kassinosopoulos M, Pitris C. Extracting morphological and sub-resolution features from optical coherence tomography images, a review with applications in cancer diagnosis. In *Photonics 2023* Jan 3 (Vol. 10, No. 1, p. 51). MDPI. DOI: 10.3390/photonics10010051
- [34] Hoque MZ, Keskinarkaus A, Nyberg P, Seppänen T. Stain normalization methods for histopathology image analysis: A comprehensive review and experimental comparison. *Information Fusion*. 2024 Feb 1;102:101997. DOI: 10.1016/j.inffus.2023.101997
- [35] Magdálek J, Makovický P, Vadlejch J. Nematode-induced pathological lesions and alterations of mucin pattern identified in abomasa of wild ruminants. *International Journal for Parasitology: Parasites and Wildlife*. 2021 Apr 1;14:62-7. DOI: 10.1016/j.ijppaw.2021.01.006
- [36] Estephan MF, Perks R. Developing Optical Sensors with Application of Cancer Detection by Elastic Light Scattering Spectroscopy. *International Journal of Biomedical and Biological Engineering*. 2024 May 27;18(5):122-36. DOI: 10.46300/9104.2024.18.122
- [37] Zheng YL, Zheng YN, Li CF, Gao JN, Zhang XY, Li XY, Zhou D, Wen M. Comparison of different machine models based on multi-phase computed tomography radiomic analysis to differentiate parotid basal cell adenoma from pleomorphic adenoma. *Frontiers in Oncology*. 2022 Jul 12;12:889833. DOI: 10.3389/fonc.2022.889833
- [38] Khan MA, Ashraf I, Alhaisoni M, Damaševičius R, Scherer R, Rehman A, Bukhari SA. Multimodal brain tumor classification using deep learning and robust feature selection: A machine learning application for radiologists. *Diagnostics*. 2020 Aug 6;10(8):565. DOI: 10.3390/diagnostics10080565
- [39] Sha X, Wang C, Qi S, Yuan X, Zhang H, Yang J. The efficacy of CBCT-based radiomics techniques in differentiating between conventional and unicystic ameloblastoma. *Oral Surgery, Oral Medicine, Oral Pathology and Oral Radiology*. 2024 Nov 1;138(5):656-65. DOI: 10.1016/j.oooo.2024.04.002
- [40] DeStigter K, Pool KL, Leslie A, Hussain S, Tan BS, Donoso-Bach L, Andronikou S. Optimizing integrated imaging service delivery by tier in low-resource health systems. *Insights into Imaging*. 2021 Dec;12:1-1. DOI: 10.1186/s13244-021-01074-6