

**Case Study****Differentiation Syndrome; Post-ATRA/ATO Induction Therapy in Acute Promyelocytic Leukemia**Kanwal Karim¹, Simab Pervaiz¹, Ina Abdul Majeed², Sana Mushtaq³ and Hina Arshad³¹Shalamar Nursing College, Lahore, Pakistan²The Aga Khan School of Nursing and Midwifery, Karachi, Pakistan³Saida Waheed FMH College of Nursing, Lahore, Pakistan

ARTICLE INFO

Key Words:

Acute, Promyelocytic, Leukemia, Differentiation Syndrome

How to Cite:Karim, K., Pervaiz, S., Majeed, I. A., Mushtaq, S., & Arshad, H. (2023). Differentiation Syndrome; Post-ATRA/ATO Induction Therapy in Acute Promyelocytic Leukemia: Acute Promyelocytic Leukemia. *Pakistan Journal of Health Sciences*, 4(10).
<https://doi.org/10.54393/pjhs.v4i10.1070>***Corresponding Author:**Kanwal Karim
Shalamar Nursing College, Lahore, Pakistan
kanwalkarim03@gmail.comReceived Date: 25th September, 2023Acceptance Date: 15th October, 2023Published Date: 31st October, 2023

ABSTRACT

Acute promyelocytic leukemia (APL) is a disease described as definite morphological and cytogenetical abnormalities and leads to coagulopathy leaving the patient in a life-threatening condition. A specific chromosomal translocation of 15 and 17 chromosomes leads to retinoic acid receptor- α ($RAR\alpha$) and promyelocytic leukemia (PML) genes fusion that produces an abnormal gene mutation forming an oncogenic protein which is (PML- $RAR\alpha$). Those APL patients, who have been treated with all-trans retinoic acid (ATRA) or arsenic trioxide (ATO) usually ends up in a complicated condition called differentiation syndrome which is rarely severe. This case report explains the 37-years old male diagnosed with acute promyelocytic leukemia and later developed a differentiation syndrome after initiation of all-trans retinoic acid and arsenic trioxide induction therapy.

INTRODUCTION

Acute promyelocytic leukemia (APL) is a disease described as definite morphological and cytogenetical abnormalities and leads to coagulopathy leaving the patient in a life-threatening condition. A specific chromosomal translocation of 15 and 17 chromosomes leads to retinoic acid receptor- α ($RAR\alpha$) and promyelocytic leukemia (PML) genes fusion that produces an abnormal gene mutation forming an oncogenic protein which is (PML- $RAR\alpha$) [1]. APL accounts for 7% to 8% of Acute Myeloid Leukemia (AML) cases. APL is common in middle-aged people and diagnose usually after the age of 20 and is more common in females [2, 3]. The diagnosis of APL is dependent on the clinical finding which includes complete blood count and

peripheral smear to assess the cell morphological changes. The abnormal cells are bi-lobular, creased nuclei and many violet color granules (Auer rods) in the cytoplasm [4]. Diagnosis of APL includes cytochemistry, immunohistochemistry, and analysis of molecular genetics according to the WHO classification system [4]. Patients managed with ATRA or ATO have complicated condition called differentiation syndrome which is rarely severe. The characteristic symptoms of differentiation syndrome include dyspnea, fever, hypotension, weight gain, acute kidney injury, and changes in the chest radiograph indicating infiltrates [5]. The treatment with ATRA or ATO has increased the prognosis by improving the remission

rate by 90% and cure patients by 80% [6].

CASE REPORT

A 37-year-old male with no-known co-morbid readmitted to the hospital in the emergency department with complaints of fever, and blood in the urine. Bone marrow analysis was done on the previous admission to rule out bicytopenia (WBC- $0.7 \times 10^9/L$ and Platelets- $7 \times 10^9/L$) and results were consistent with APL. Flow cytometry and PML RARA were obtained. The patient and the family were counseled regarding the situation, risks, and various options for treatment along with the plan of care. The patient was then initiated with ATRA and ATO. During treatment the patient started experienced worsening shortness of breath, chest x-ray showed minimal basal atelectasis (Figure 1 and 2). ATRA and ATO administration was stopped and supplemental oxygen therapy, steroids, antibiotics, and diuretics were started. The oxygen requirement increased and patient was electively intubated and managed along the lines of differentiation Syndrome.

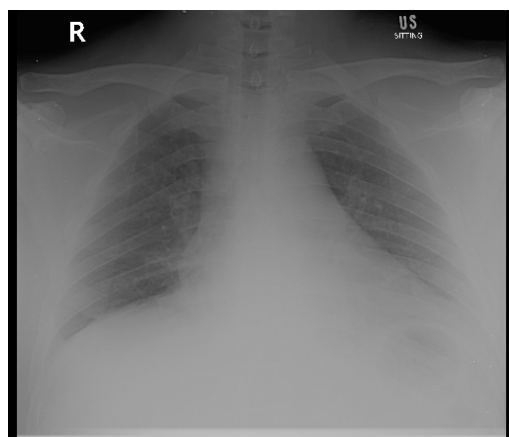


Figure 1: At the initiation of symptoms

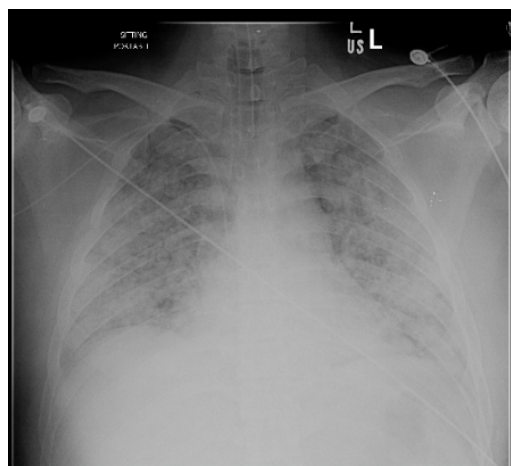


Figure 2: After intubation

DISCUSSION

Differentiation syndrome is a serious difficulty that arises

after the initiation of induction therapy with ATRA or ATO, or both in patients with APL. The incidence of cases with DS after the initiation of treatment, according to the standardized doses is approximately 2 to 27% after the administration of ATRA and approximately 7 to 31% after ATO [7]. According to the systematic review, it is found that the incidence of DS individually with ATRA is 17.4% whereas those who treated with ATRA and ATO are 23.3% [8]. Fever and common respiratory signs and symptoms are the specific features seen in patients with differentiation syndrome [6]. The onset of differentiation syndrome with the initiation of therapy is within days to weeks, but it varies from patient to patient [9]. The incidence of symptoms with differentiation syndrome include dyspnea (77%), pleural effusion (43%), pericardial effusion (17%), fever (64%), weight gain (53%), generalized edema (67%), acute renal failure (28%), and hypotension (26%) [10]. The pathophysiology of DS is not known but it has been discovered that the administration of ATRA induces a pathophysiologic response and leads to initiate systemic inflammatory response syndrome (SIRS). The inflammatory response activates the release of tumor necrosis factor- α and cytokines like interleukin-1, which is mostly involved in the damage of endothelial cells [9]. As a result of inflammation, blast cell infiltration occurs in the lungs. It is a similar mechanism in which the normal granulocytes migrate to the site of inflammation and the circulating leukocytes were taken by the endothelium cells. The transmigration through the endothelial cell requires protease secretion which ultimately disrupts the barrier. Extravasation of fluid that occurs in the lung leads to pleural effusion [11]. The management of DS include administration of corticosteroids at the first suspicion and diagnostic testing is in progress. For immediate response, corticosteroids may be used twice a day to decrease the severity of symptoms. Moreover, hydroxyurea may be initiated in patients with associated leukocytosis. In edematous or patients with pleural effusion, the most common drug of choice is furosemide. Therefore, patients experiencing severe pulmonary and renal symptoms require close monitoring and hospitalization [12]. ATRA has been widely used for the management of APL for decades and along with induction therapy with ATRA, it is recommended to simultaneously treat patients with a higher dose of dexamethasone in those who have significant symptoms of DS [13]. Furthermore, it is found that combination therapy of ATRA and ATO have a high effect on patients with APL regardless of any risk. A randomized control trial study showed that treatment of APL with ATRA or ATO or both in all risk groups showed the same results with increased cure, less relapse, and no difference in survival rate [14]. Therapy can be temporarily

discontinued, in the case mentioned, the treatment was hold at the onset of respiratory symptoms and later the therapy with ATRA and ATO was restarted as it is considered to be significant management in all risk groups [15]. Moreover, ATO has an effect on heart rhythm and QT prolongation which is an evident side effect. This is consistent with the above-mentioned case. So, ATO was stopped after 24 hours.

CONCLUSIONS

In the case mentioned, the patient become dyspneic, and the condition worsened and the patient ended up on ventilatory support. The recovery was gradual and the treatment regimen for APL restarted. On the other hand, the advanced practice nurse (APN) along with the physicians should look at the marker of disease progression in patients to recognize the severity of symptoms of differentiation syndrome.

Authors Contribution

Conceptualization: KK

Methodology: SP

Formal analysis: IAM

Writing-review and editing: SM, HA, KK

All authors have read and agreed to the published version of the manuscript.

Conflicts of Interest

The authors declare no conflict of interest.

Source of Funding

The authors received no financial support for the research, authorship and/or publication of this article.

REFERENCES

- [1] Watts JM and Tallman MS. Acute promyelocytic leukemia: what is the new standard of care? *Blood Reviews*. 2014 Sep; 28(5): 205-12. doi: 10.1016/j.blre.2014.07.001.
- [2] Cingam SR and Koshy NV. *Acute Promyelocytic Leukemia*. StatPearls Publishing; 2022.
- [3] Sullivan EJ and Decker PJ. Effective leadership and management in nursing. *AJN The American Journal of Nursing*. 1998 Jun; 98(6): 16L. doi: 10.1097/00000446-199806000-00014.
- [4] Barbui T, Thiele J, Gisslinger H, Kvasnicka HM, Vannucchi AM, Guglielmelli P, et al. The 2016 WHO classification and diagnostic criteria for myeloproliferative neoplasms: document summary and in-depth discussion. *Blood Cancer Journal*. 2018 Feb; 8(2): 15. doi: /10.1038/s41408-018-0054-y.
- [5] Stahl M and Tallman MS. Differentiation syndrome in acute promyelocytic leukaemia. *British Journal of Haematology*. 2019 Oct; 187(2): 157-62. doi: 10.1111/bjh.16151.
- [6] Sarkar S, Ghosh P, Gehani A, Ghara N, Bhattacharyya P. Multidisciplinary corroboration in differentiation syndrome: a case report. *Journal of Medical Case Reports*. 2021 Dec; 15(1): 1-5. doi: 10.1186/s13256-021-02790-w.
- [7] Montesinos P and Sanz MA. The differentiation syndrome in patients with acute promyelocytic leukemia: experience of the pethema group and review of the literature. *Mediterranean Journal of Hematology and Infectious Diseases*. 2011 Dec; 3(1): e2011059. doi: 10.4084/MJHID.2011.059.
- [8] Gasparovic L, Weiler S, Higi L, Burden AM. Incidence of differentiation syndrome associated with treatment regimens in acute myeloid leukemia: a systematic review of the literature. *Journal of Clinical Medicine*. 2020 Oct; 9(10): 3342. doi: 10.3390/jcm9103342
- [9] Sanz MA and Montesinos P. How we prevent and treat differentiation syndrome in patients with acute promyelocytic leukemia. *Blood, The Journal of the American Society of Hematology*. 2014 May; 123(18): 2777-82. doi: 10.1182/blood-2013-10-512640.
- [10] Norsworthy KJ, Mulkey F, Scott EC, Ward AF, Przepiorka D, Charlab R, et al. Differentiation syndrome with ivosidenib and enasidenib treatment in patients .with relapsed or refractory IDH-mutated AML: a US Food and Drug Administration systematic analysis. *Clinical Cancer Research*. 2020 Aug; 26(16): 4280-8. doi: 10.1158/1078-0432.CCR-20-0834.
- [11] Rego EM and De Santis GC. Differentiation syndrome in promyelocytic leukemia: clinical presentation, pathogenesis and treatment. *Mediterranean Journal of Hematology and Infectious Diseases*. 2011 Oct; 3(1): e2011048. doi: 10.4084/MJHID.2011.048.
- [12] Larson RA, Bag R, Lowenberg B, Rosmarin AG. Differentiation syndrome associated with treatment of acute leukemia. *UpToDate*. 2023 Jul.
- [13] Frankel SR, Eardley A, Lauwers G, Weiss M, Warrell Jr RP. The " retinoic acid syndrome" in acute promyelocytic leukemia. *Annals of Internal Medicine*. 1992 Aug; 117(4): 292-6. doi: 10.7326/0003-4819-117-4-292.
- [14] Burnett AK, Russell NH, Hills RK, Bowen D, Kell J, Knapper S, et al. Arsenic trioxide and all-trans retinoic acid treatment for acute promyelocytic leukaemia in all risk groups (AML17): results of a randomised, controlled, phase 3 trial. *The Lancet Oncology*. 2015 Oct; 16(13): 1295-305. doi: 10.1016/S1470-2045(15)00193-X.
- [15] Reyhanoglu G, Hughes B, King KE, Cambridge R. Differentiation syndrome, a side effect from the therapy of acute promyelocytic leukemia. *Cureus*. 2020 Dec; 12(12): e12042. doi: 10.7759/cureus.12042.