



Systematic Review



Assessing the Etiology and Pathogenesis of Pyogenic Granuloma in Gingival Tissues

Aasiya Kazi¹, Uzma Tariq², Zobia Nissa², Syeda Sadia Hassan³, Arsalan Ahmed⁴, Shahzaman Memon⁵, Shaharyar Ahsan^{6*}, Maheen Ejaz⁷ and Danish Noor⁸

¹Department of Periodontology, Isra University, Hyderabad, Pakistan

²Department of Oral Pathology, Isra University, Hyderabad, Pakistan

³Department of Oral Biology, Isra University, Hyderabad, Pakistan

⁴Department of Periodontics, Muhammad Dental College, Mirpurkhas, Pakistan

⁵Department of Oral Pathology, Muhammad Dental College, Ibn E Sina University, Mirpurkhas, Pakistan

⁶Department of Research and Development, Scientia Nova, Islamabad, Pakistan

⁷Functional Genomics Laboratory, Comsats University, Islamabad, Pakistan

⁸Department of Medicine, Khan Research Laboratories Hospital, Islamabad, Pakistan

ARTICLE INFO

Keywords:

Gingival Pyogenic Granuloma, Oral Hygiene, Inflammation, Gingival Tissue

How to Cite:

Kazi, A., Tariq, U., Nissa, Z., Hassan, S. S., Ahmed, A., Memon, S., Ahsan, S., Ejaz, M., & Noor, D. (2025). Assessing the Etiology and Pathogenesis of Pyogenic Granuloma in Gingival Tissues: Pathogenesis of Pyogenic Granuloma in Gingival Tissues. *Pakistan Journal of Health Sciences*, 6(3), 296-302. <https://doi.org/10.54393/pjhs.v6i3.2281>

*Corresponding Author:

Shaharyar Ahsan
Department of Research and Development, Scientia Nova, Islamabad, Pakistan
shaharyarhasanofficial@gmail.com

Received date: 24th September, 2024

Acceptance date: 5th March, 2025

Published date: 31st March, 2025

ABSTRACT

Pyogenic granuloma is a benign, rapidly growing vascular lesion commonly found on mucous membranes. Although its demographic distribution is well documented, the specific etiology and pathogenesis of pyogenic granuloma in gingival tissues remain poorly understood.

Objectives: To evaluate the etiology and pathogenesis of pyogenic granuloma in gingival tissues. **Methods:** Databases including PubMed, Google Scholar, Cochrane Library, Springer, and Science Direct were searched from January 2009 to February 2024. Prisma guidelines were followed and 20 studies meeting the criteria were included in the systematic review. **Results:** These results indicate the significant role of etiological factors such as poor oral hygiene, trauma, local irritation, and hormonal factors in the development of pyogenic granuloma. Patients with pyogenic granuloma showed gingival inflammation, thick bundles of collagen fibers, proliferating endothelial cells, overexpression of vascular molecules and CD4+ cells, and a plethora of neutrophils. **Conclusions:** It was concluded that pyogenic granuloma in gingival tissues is predominantly associated with local irritants, poor oral hygiene, chronic trauma, and hormonal imbalances. These factors trigger inflammatory responses and vascular proliferation, suggesting that targeted interventions such as enhanced oral care and management of hormonal levels could improve prevention and treatment outcomes for gingival pyogenic granuloma.

INTRODUCTION

Pyogenic granuloma (PG) is a benign, non-neoplastic proliferation of connective tissue characterized by granulation tissue hyperplasia. It is a common soft tissue lesion, particularly affecting skin and mucous membranes. While first described in 1844 by Hullihen, it was Poncet and Dor who, in 1897, coined the term "botryomycosis hominis" for similar vascular tumors. The current term, "pyogenic granuloma," was introduced by Hartzell in 1904 [1]. PG can

manifest in two forms: lobular capillary hemangioma (LCH) and non-lobular capillary hemangioma (non-LCH). It can occur at any age but is most prevalent in young adults, with a higher incidence in females, especially during pregnancy. Hormonal factors, particularly increased estrogen and progesterone levels may contribute to its development during pregnancy by stimulating angiogenesis [2]. Clinically, PG presents as a raised, smooth, exophytic mass

with a reddish, hemorrhagic appearance. It can be either sessile or pedunculated, with the majority being sessile [3]. The lesion progresses through three phases: cellular, capillary, and involutary. Its colour can vary from pink to reddish-purple, depending on vascularity. Early lesions are often pink, while advanced lesions become increasingly red or purple. Typically, PG grows slowly and is asymptomatic [4]. However, in some cases, it can grow rapidly and stabilize at a certain size. The lesion size can range from a few millimetres to several centimeters, with the marginal gingiva being a more common site than the alveolar part [5]. Diverse factors have been implicated in developing pyogenic granulomas (PGs), which affect the skin and oral cavity. Historically, bacterial infections were considered the primary cause. However, recent findings suggest a different etiology, as PGs are not associated with infection and lack pus or complete granulomas on histological examination. Potential contributing factors include chronic low-grade trauma, physical injury, hormonal influences, microorganisms, and certain medications. Oral PGs, which constitute 75% of cases, are often linked to local irritants such as dental calculus, and foreign bodies lodged in the gingiva [6]. Gingival PG is the most common tumor-like growth in the oral cavity mostly developing around the anterior teeth and is considered to be neoplastic. The majority of gingival PGs develop at the marginal gingiva. Gingival PGs are more common in the second and third decades of life [7]. The International Society for the Study of Vascular Anomalies (ISSVA, 2022) classifies some PGs, such as Langerhans cell histiocytosis (LCH), as vascular tumors. Angelopoulos AP proposed "hemangiomas" as a more accurate descriptor, reflecting the histopathological similarity to hemangiomas and the inflammatory nature of PGs. Definitive diagnosis relies on histopathological examination. Therapeutic options for PGs include surgical excision, which is the standard approach [8]. Additional treatments may involve carbon dioxide laser therapy, pulsed dye laser therapy, cryosurgery, electrodesiccation, and intralesional corticosteroid injections. While the risk of malignant transformation is generally low, recurrence rates can be as high as 16%, necessitating re-excision [9]. Recurrence may be attributed to incomplete excision, persistent underlying causes, or re-injury to the lesion site [10, 11]. A comprehensive review of existing literature reveals a lack of high-quality evidence on the underlying causes and mechanisms of PG in gingival tissues. The literature is particularly lacking in studies that delve into various etiologies and pathogenic processes of PG. This study aims to comprehensively assess the etiology and pathogenesis of PG in gingival tissues.

METHODS

A comprehensive literature search was conducted using PubMed and Google Scholar to identify relevant studies published between January 2009 and February 2024. The search strategy adhered to the PRISMA guidelines and employed the following keywords: "pyogenic granuloma," "gingival tissue," "pathogenesis," and "etiology." The primary focus was on original research articles that evaluated the etiology and pathogenesis of pyogenic granuloma in gingival tissues. Reference lists of included studies were manually searched to identify additional eligible studies. Studies were included or excluded based on predefined criteria (Table 1).

Table 1: Inclusion and Exclusion Criteria

Inclusion Criteria	Exclusion Criteria
Papers published between January 2009 to February 2024	Duplication publication
Directly linked to the etiopathogenesis of PG in gingival tissues	Not directly linked to the etiopathogenesis of PG in gingival tissues
English language	Not written in English
Papers mentioning the evaluation of the etiology and pathogenesis of PG in gingival tissues	Not mentioning the etiology and pathogenesis of PG in gingival tissues.
Full-text systematic reviews, case reports, case series, meta-analyses, RCTs, prospective studies, cohort studies, case reports, observational study	Editorials, conference papers, letters to the editor, short communications, meeting abstracts

Initially, 6,582 studies were identified. After screening titles and abstracts, 2,000 potential studies were selected for full-text review. Ultimately, 20 studies met the inclusion criteria and were included in the qualitative synthesis. The inclusion and exclusion criteria were developed following PRISMA guidelines to make sure that only high-quality studies that were relevant to the research question were selected. As a result, irrelevant, outmoded, and methodologically defective studies were excluded while defining population, intervention, comparison, outcomes, and study designs (PICOS). A systematic and structured approach was implemented to ensure data accuracy and consistency. Two reviewers independently extracted relevant data such as study characteristics, participant demographics, interventions, and outcomes using a standardized spreadsheet developed specifically for this review. Before full data extraction, the reviewers conducted a calibration exercise on a sample of studies to ensure that key variables were consistently identified and recorded. Discrepancies between the reviewers were resolved through discussion, and when necessary, a third reviewer was consulted to reach a consensus. Furthermore, periodic cross-checks were performed against the original articles to verify data accuracy. This rigorous process aimed to minimize Identification of Studies Via Databases bias and enhance the reproducibility

of our findings(Figure 1).

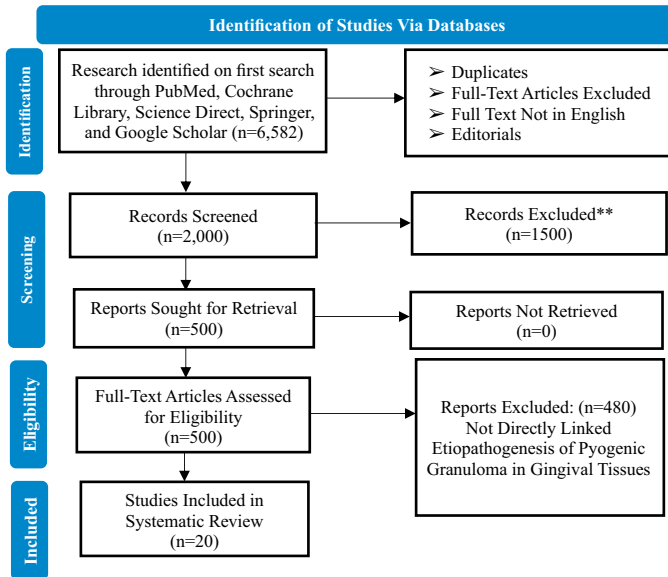


Figure 1: Screened Studies Included in the Systematic Review

RESULTS

This systematic review yielded a total of 20 studies, of which, nine were case reports, and five were comparative

Table 2: Summary of Study Findings Evaluated

Sr. no	Study Design	Country	Total Participants	Etiopathogenesis	Evaluation Method	References
1	Case report	India	1 male patient	Calculus in the mouth, engorged blood vessels, inflammatory cells, thick collagen fibers	Histopathological report	[12]
2	Case report and literature review	Mexico	3 female patients	Ulcerated surface, local irritants, diffused lymphoplasmacytic type inflammatory infiltrates, stromal hemorrhage	Histological examination	[13]
3	Case series	Nepal	4 patients	Proliferating perivascular inflammatory infiltration, thick bundles of collagen fibers widespread in the stroma	Histopathological investigation	[14]
4	Narrative review	Mexico	Not specified	Hypersensitivity to certain drugs, hormonal factors, gingival inflammation	Histopathological report	[15]
5	Case report	India	30-year-old male patient	Proliferating endothelial cells, lymphatic vessels	Histopathological investigation	[16]
6	Case report	India	28-year-old female patient	Increased estrogen and progesterone levels	Clinical examination	[17]
7	A series of case reports	India	6 female patients	Excessive infiltrate of neutrophils	Histopathological investigation	[18]
8	Case report	India	1 year-old child	Excessive infiltration of neutrophils, poor oral hygiene	Histopathological investigation	[19]
9	Case report	India	Not specified	Ulceration, hyperplasia	Histopathological investigation	[20]
10	Case report	India	18-year-old female patient	Chronic irritation, peripheral ossifying fibroma, trabeculae vascular	Histopathological investigation	[21]
11	Literature review	India	1 patient	Excessive infiltrate of neutrophils	Histopathological examination	[22]
12	Retrospective study	China	2971 epulis cases	Excessive infiltrate of neutrophils	Medical records	[23]

studies. The remaining studies were a literature review, narrative review, and retrospective study. A combined total of 3,374 patient samples included in the studies have been evaluated in this systematic review. The analysis of the papers indicated that 10 studies are from India, two studies are from Iran, two are from Mexico, remaining are from Columbia China, Nepal, Brazil, and Greece. The country that evaluated the etiopathogenesis the most was India as per the systematic review. Eight studies reported poor oral hygiene, calculus in the mouth, chronic irritation by food impaction, hypersensitivity reactions to certain drugs, and hormonal factors as common PG etiological factors. Eight studies examined the pathogenesis of PG and revealed that a plethora of inflammatory infiltrate cells, bundles of collagen fibers, hemorrhage stroma, and proliferating endothelial cells contributed majorly to developing PG in the gingival. The remaining studies evaluated the role of higher proliferation in LCH type of PG, excessive infiltrate of neutrophils, microorganisms in lesions, overexpression of COX-2, IL-10, and IL-4, bone resorption, and tissue destruction (Table 2).

13	Comparative study	Iran	70 samples	Higher levels of immune-histochemical expression of ICAM-1, VCAM-1, CD34 levels	Immunohistochemistry staining, paired t-test	[24]
14	Comparative study	Iran	10 PG cases	Higher proliferation in LCH	Mann-Whitney U-test	[25]
15	Comparative study	Greece	30 PG cases	Higher proliferation in LCH	Mann-Whitney U-test	[26]
16	Retrospective study	Brazil	169 samples	Higher proliferation in LCH	Histopathological investigation	[27]
17	Comparative study	Columbia	46 samples	Lesion evolution, inflammatory infiltrate masses, overexpression of IL-4, bone resorption, tissue destruction	Histopathological investigation	[28]
18	Literature review	India	Not specified	MOs in lesion	Not specified	[29]
19	Comparative study	Columbia	57 oral PG cases	Increased immune-expression of COX-2 and IL-10	Immunohistochemically assessment	[30]
20	Literature review	India	2 patients	Nonspecific infection, over-hanging restorations, cheek biting	Histopathological investigation	[31]

PG, pyogenic granuloma; LCH, lobular capillary hemangioma; IL-4, interleukin 4; MOs, microorganisms; IL-10, interleukin-10; COX-2, cyclooxygenase-2

DISCUSSION

Pyogenic granuloma (PG) is a common benign, non-neoplastic overgrowth of skin and oral tissues. Despite its name, it is not associated with pus formation or infection. Histologically, it presents as a vascular lesion rather than a granulomatous one. A case report by Gomes *et al.*, identified several potential etiological and pathological factors contributing to PG development in a 22-year-old Indian male. These included poor oral hygiene, calculus accumulation, engorged blood vessels, and the presence of inflammatory cells and collagen fibers, as revealed by histopathological examination [12]. The presence of bacteria such as *Bacteroides melaninogenicus*, *Prevotella intermedia*, *Fusobacterium*, *Staphylococcus aureus*, imbalanced angiogenesis enhancers and inhibitors such as angiopoietin-1, ephrin-B2 are the major contributors to exacerbating etiopathogenesis of PG [13]. Marla and colleagues presented a case series involving four young Nepalese patients (three women and one man) diagnosed with PG. Their histopathological findings revealed a common pattern across all four cases: proliferating inflammatory cells surrounding blood vessels and dense collagen fiber bundles infiltrating the stromal tissue [14]. A narrative review conducted by Lomeli *et al.*, in Mexico in 2023 found that PG condition can occur following hypersensitivity reactions to certain drugs such as calcineurin inhibitors, phenytoin, and antiretroviral drugs. They also reported that hormonal changes particularly estrogen and progesterone rapidly promote the development of PG by elevating levels of already present gingival inflammation in blood vessels, increasing the adhesion of platelets and leukocytes. The results of the study found ulcerated surface, bleeding on touch, local irritants, history of lesion evolution, diffused

lymphoplasmacytic type inflammatory infiltrates, large masses of fibroblasts, and stromal hemorrhage among all 3 patients [15]. Panseriya and Hungund described a unique case of pyogenic granuloma (PG) linked to a periodontal abscess and bone loss in a 30-year-old Indian male. Histopathological analysis of the lesion revealed proliferating endothelial cells and lymphatic vessels, along with thickened blood vessels and areas of pseudo-epitheliomatous hyperplasia [16]. Debnath and Chatterjee reported that hormonal changes during the third trimester of pregnancy were the main etiological factor attributable to recurrent PG twice within 2 years in the same area [17]. Adusumilli *et al.*, (2014) presented six case reports from India involving six female patients. Their findings indicated that etiological factors, including local irritants, traumatic injuries, and hormonal influences, were implicated in all six cases. Furthermore, the histopathological examinations showed ulcerated surfaces filled with excessive infiltration of neutrophils, polymorphonuclear leukocytes (PMNs), lymphocytes, and proliferation of fibroblasts [18]. Surprisingly, similar histological features were also observed in a one-year-old child as reported by Thomas *et al.*, in India in 2024. They also highlighted the etiological factors found in this case such as repeated trauma by brushing or food impaction, and failure to remove tissues causing lesions [19]. Hunasgi *et al.* reported that ulceration and hyperplasia were most commonly found in PG [20]. Lalremtluangi and fellows, assessed a female patient with long-standing PG in India. The results of the study found that poor oral hygiene, chronic irritation caused by calculus, peripheral ossifying fibroma, and trabeculae vascular were associated with reactionary bone changes in long-standing PG [21]. Meshram *et al.*, and Zhao *et al.*, independently conducted literature reviews and

retrospective studies, respectively, in India and China [22, 23]. A comparative study consisting of 70 samples was carried out by Seyedmajidi *et al.*, in Iran. Their findings revealed significantly elevated levels of ICAM-1, VCAM-1, and CD34 in periodontal pockets compared to healthy gingival tissues ($p < 0.001$ for all comparisons). These vascular adhesion molecules and endothelial cell markers were identified as potential biomarkers for periodontal disease pathogenesis [24]. Rezvani *et al.*, demonstrated that Langerhans cell histiocytosis (LCH) is associated with increased endothelial cell proliferation compared to non-LCH cases [25]. Another comparative study conducted by Epivatianos *et al.*, in Greece found that non-LCH PG (86.4%) compared to LCH was associated more frequently with the PG etiopathological factors [26]. Ribeiro *et al.*, conducted an 18-year retrospective study in Brazil and reported comparable outcomes [27]. González-Pérez *et al.*, reported that lesion evolution, inflammatory infiltrate masses, overexpression of IL-4, bone resorption, and tissue destruction may act as predictors of gingival PG [28]. Sharma *et al.*, found that trauma is usually the causative factor for PG in buccal mucosa, lips, tongue, and palate. They also revealed various mechanisms of pathogenesis such as the plethora of inflammatory angiogenesis factors such as persistent injury by faulty filling and food impaction, and increased estrogen or progesterone levels [29]. Isaza-Guzman and colleagues performed a comparative study of 57 oral squamous cell carcinoma cases in Colombia. Their immune-histochemical analysis revealed elevated expression of both cyclooxygenase-2 (COX-2) and interleukin-10 (IL-10) in all cases [30]. Verma *et al.*, conducted 2 PG case series (consisting of 1 male and 1 female aged < 30 years) in India and concluded that nonspecific infection, overhanging restorations, and cheek biting may lead to the underlying fibro-vascular connective tissue-promoting formation of PG in all 6 cases [31]. According to our study, the development of PG is multifactorial, being dependent on both, independent and interrelated factors. Factors that can independently trigger PG development include trauma (cheek biting, brushing injuries, etc) hormonal changes (elevated estrogen and progesterone levels), hypersensitivity to drugs, bacterial infections, and genetic markers (e.g., ICAM-1 and VCAM-1 expression) while interrelated factors work together towards the development of PG and include chronic irritation (e.g., calculus accumulation), inflammatory processes, and abnormal angiogenesis (mediated by inflammatory markers and endothelial proliferation). This suggests a complex interconnection of these causative factors where inflammation initiates the pathogenesis while hormonal changes and bacterial overload in the oral cavity exacerbate the condition [32]. The role of CD4 cells and neutrophils was observed in the pathogenesis of gingival pyogenic granuloma [33]. CD4+ cells release cytokines (IL-4 and IL-10) contributing to chronic inflammation and dysregulated fibro-vascular

proliferation which is seen in gingival pyogenic granuloma. Whereas neutrophils, being the first responders of the innate immune system, play their role by secreting reactive oxygen species, matrix metalloproteinase and pro-inflammatory cytokines ultimately leading to tissue degradation and remodeling, setting up a background of vascular engorgement and endothelial cell proliferation which are the characteristic features of PG pathogenesis [34]. CD4+ cells and neutrophils make a feedback loop of inflammation and vascular remodeling leading to the exacerbation of gingival PG lesions [35]. Prevention options include maintaining good oral hygiene, avoiding local irritants such as overhanging dental restorations and food impactions, and dose adjustments or changing the drugs that are known to trigger PG to other alternatives [36]. Treatment includes non-surgical and surgical interventions, hormonal management and pharmacological treatment. Initial management includes scaling and root planning to remove calculus which reduces inflammation and lesion size [37]. Complete excision of the lesion is the gold standard [38]. Diode laser excision offers less bleeding and faster healing [39]. Cryotherapy, electrodesiccation and pulse dye laser therapy can also be considered [40]. Local steroid application can be considered in some cases [8, 9]. In pregnancy-related cases, postpartum regression is observed so surgical treatment should be delayed until there is any complication. Hence, a multidisciplinary approach including expertise from periodontists and general practitioners should be used for optimal management of PG [10, 11]. This review identified multiple studies that evaluated correlations regarding hormonal factors across genders and age groups. For instance, Koo *et al.*, found that oral PG occurs mostly in the first and third decade of life in males and fourth to fifth decade in females. So there is a statistically significant difference in occurrence between genders across different age groups ($p < 0.05$) [11]. Although our review is narrative, these findings suggest that hormonal variations may play a role in the pathophysiology of the conditions under review. However, heterogeneity in study design and sample characteristics limits our ability to generalize these findings. Future research employing a meta-analytical approach could help clarify these associations further.

CONCLUSIONS

It was concluded that this study highlighted the various etiopathogenesis factors of gingival PG such as poor oral hygiene, calculus, hypersensitivity reactions to certain drugs, chronic irritation caused by food impaction, trauma by forceful tooth-brushing or cheek biting, a bundle of inflammatory masses, overexpression of immune-histochemical, angiogenesis and hormonal factors, the proliferation of endothelial cells, stromal hemorrhage, gingival inflammation in blood vessels, and abundance of

anaerobic and aerobic bacteria. This systematic review underscores the importance of practicing preventive measures which include oral hygiene, avoiding trauma to gingiva and drugs known to trigger PG. This study provides insights into the etiopathogenesis of PG that can help clinicians in designing targeted treatment strategies, highlighting the need for a multidisciplinary treatment approach to reduce lesion recurrence and improve clinical outcomes.

Authors Contribution

Conceptualization: AK

Methodology: AK, ME, DN

Formal analysis: DN

Writing review and editing: UT, A, SSH, AA, SM, SA

All authors have read and agreed to the published version of the manuscript

Conflicts of Interest

All the authors declare no conflict of interest.

Source of Funding

The author received no financial support for the research, authorship and/or publication of this article.

REFERENCES

- [1] Kaleeny JD and Janis JE. Pyogenic Granuloma Diagnosis and Management: A Practical Review. *Plastic and Reconstructive Surgery-Global Open*. 2024Sep;12(9):e6160. doi:10.1097/GOX.00000000000006160.
- [2] De Oliveira LE, E Lima CB, Ito FA, De Lima HG, Junior AT. Pyogenic Granuloma in A Transgender Woman: Possible Association to the Hormonal Therapy. *Research, Society and Development*. 2021;10(6).doi: 10.33448/rsd-v10i6.15408.
- [3] Luna-Ceron E, Gómez-Gutiérrez AK, Gonzalez-Hernandez C, Gatica-Torres M. An Uncommon Presentation of Pyogenic Granuloma. *Cureus*. 2021 Jan; 13(1). doi: 10.7759/cureus.12509.
- [4] Zainuddin NI. Red Lump on the Gum: Pyogenic Granuloma. In *Clinicopathological Correlation of Oral Diseases*. Cham: Springer International Publishing. 2023 Jul: 213-219. doi: 10.1007/978-3-031-24408-7_19.
- [5] Nemade SV, Shinde KJ. Granulomatous diseases in otorhinolaryngology, head and neck. *Springer*. 2021: 283-287. doi: 10.1007/978-981-16-4047-6_31.
- [6] Plachouri KM and Georgiou S. Therapeutic Approaches to Pyogenic Granuloma: An Updated Review. *International Journal of Dermatology*. 2019 Jun; 58(6): 642-8. doi: 10.1111/ijd.14268.
- [7] Sonar PR and Panchbhai AS. Pyogenic Granuloma in the Mandibular Anterior Gingiva: A Case Study. *Cureus*. 2024 Jan; 16(1). doi: 10.7759/cureus.52273.
- [8] Chilukuri S, Kallam AR, Gudeli V, Kolu KV, Natukula K. Reclassification and Histopathological Study of Vascular Anomalies According to ISSVA (2018 Revision) Classification. *Journal of Medical and Scientific Research*. 2021;9:204-10. doi:10.17727/JMSR.2021/9-31.
- [9] Lee J, Sinno H, Tahiri Y, Gilardino MS. Treatment Options for Cutaneous Pyogenic Granulomas: A Review. *Journal of Plastic, Reconstructive and Aesthetic Surgery*. 2011Sep;64(9):1216-20. doi:10.1016/j.bjps.2010.12.021.
- [10] Wollina U, Langner D, França K, Gianfaldoni S, Lotti T, Tchernev G. Pyogenic Granuloma—A Common Benign Vascular Tumor with Variable Clinical Presentation: New Findings and Treatment Options. *Open Access Macedonian Journal of Medical Sciences*. 2017Jul; 5(4): 423. doi: 10.3889/oamjms.2017.111.
- [11] Koo MG, Lee SH, Han SE. Pyogenic Granuloma: A Retrospective Analysis of Cases Treated Over A 10-Year. *Archives of Craniofacial Surgery*. 2017Mar;18(1): 16. doi: 10.7181/acfs.2017.18.1.16.
- [12] Gomes SR, Shakir QJ, Thaker PV, Tavadia JK. Pyogenic Granuloma of the Gingiva: A Misnomer? –A Case Report and Review of Literature. *Journal of Indian Society of Periodontology*. 2013Jul;17(4):514-9. doi:10.4103/0972-124X.118327.
- [13] Martínez SM, Morando DB, González AE, Sandoval JR. Unusual Clinical Presentation of Oral Pyogenic Granuloma with Severe Alveolar Bone Loss: A Case Report and Review of Literature. *World Journal of Clinical Cases*. 2023Jun;11(16):3907. doi:10.12998/wjcc.v11.i16.3907.
- [14] Marla V, Shrestha A, Goel K, Shrestha S. The Histopathological Spectrum of Pyogenic Granuloma: A Case Series. *Case Reports in Dentistry*. 2016; 2016(1): 1323798. doi: 10.1155/2016/1323798.
- [15] Lomeli Martinez SM, Carrillo Contreras NG, Gómez Sandoval JR, Zepeda Nuño JS, Gomez Mireles JC, Varela Hernández JJ et al. Oral Pyogenic Granuloma: A Narrative Review. *International Journal of Molecular Sciences*. 2023 Nov;24(23):16885. doi:10.3390/ijms242316885.
- [16] Panseriya BJ and Hungund S. Pyogenic Granuloma Associated with Periodontal Abscess and Bone Loss—A Rare Case Report. *Contemporary Clinical Dentistry*. 2011 Jul; 2(3): 240-4. doi: 10.4103/0976-237X.86478.
- [17] Debnath K and Chatterjee A. Management of Recurrent Pyogenic Granuloma with Platelet-Rich Fibrin Membrane. *Journal of Indian Society of Periodontology*. 2018Jul;22(4):360-4. doi:10.4103/jisp.jisp_86_18.
- [18] Adusumilli S, Yalamanchili PS, Manthena S. Pyogenic Granuloma Near the Midline of the Oral Cavity: A Series of Case Reports. *Journal of Indian Society of Periodontology*. 2014 Mar;18(2):236-9. doi:10.4103/0972-124X.131339.

- [19] Thomas JM, Subbalekshmi T, Jame JP, Baby T, George MA, Anandhukrishnan E et al. Pyogenic Granuloma in a One-Year-Old Child: A Rare Entity. *Cureus*. 2024 Mar; 16(3). doi: 10.7759/cureus.55487.
- [20] Hunasgi S, Koneru A, Vanishree M, Manvikar V. Assessment of Reactive Gingival Lesions of Oral Cavity: A Histopathological Study. *Journal of Oral and Maxillofacial Pathology*. 2017 Jan; 21(1):180. doi: 10.4103/jomfp.JOMFP_23_16.
- [21] Lalremtluangi R, Dangore-Khasbage S, Ralte R. Reactionary Bone Changes in Long-Standing Pyogenic Granuloma: A Case Report. *Cureus*. 2024 Jan; 16(1). doi: 10.7759/cureus.53021.
- [22] Meshram M, Durge K, Shirbhate U, Meshram Sr M. An Overview of Oral Pyogenic Granuloma and Its Management: A Case Report. *Cureus*. 2023 Nov; 15(11). doi: 10.7759/cureus.48305.
- [23] Zhao N, Yesibulati Y, Xiayizhati P, He YN, Xia RH, Yan XZ. A Large-Cohort Study of 2971 Cases of Epulis: Focusing On Risk Factors Associated with Recurrence. *BioMed Central Oral Health*. 2023 Apr; 23(1): 229. doi: 10.1186/s12903-023-02935-x.
- [24] Seyedmajidi M, Shafae S, Hashemipour G, Bijani A, Ehsani H. Immuno-Histochemical Evaluation of Angiogenesis Related Markers in Pyogenic Granuloma of Gingiva. *Asian Pacific Journal of Cancer Prevention*. 2015; 16(17):7513-6. doi: 10.7314/APJCP. 2015.16. 17.7513.
- [25] Rezvani G, Azarpira N, Bitra G, Zeynab R. Proliferative Activity in Oral Pyogenic Granuloma: A Comparative Immune-Histochemical Study. *Indian Journal of Pathology and Microbiology*. 2010 Jul; 53(3): 403-7. doi: 10.4103/0377-4929.68242.
- [26] Epivatianos A, Antoniadou D, Zaraboukas T, Zairi E, Pouloupoulos A, Kiziridou A et al. Pyogenic Granuloma of the Oral Cavity: Comparative Study of Its Clinicopathological and Immuno-Histochemical Features. *Pathology International*. 2005 Jul; 55(7):391-7. doi: 10.1111/j.1440-1827.2005.01843.x.
- [27] Ribeiro JL, Moraes RM, Carvalho BF, Nascimento AO, Milhan NV, Anbinder AL. Oral Pyogenic Granuloma: An 18-Year Retrospective Clinicopathological and Immune-Histochemical Study. *Journal of Cutaneous Pathology*. 2021 Jul; 48(7):863-9. doi: 10.1111/cup.13970.
- [28] González-Pérez LV, Isaza-Guzmán DM, Tobón-Arroyave SI. Association Study Between Clinicopathological Variables and Periodontal Breakdown in Gingival Pyogenic Granuloma. *Clinical Oral Investigations*. 2014 Dec; 18: 2137-49. doi: 10.1007/s00784-014-1195-4.
- [29] Sharma S, Chandra S, Gupta S, Srivastava S. Heterogeneous Conceptualization of Etiopathogenesis: Oral Pyogenic Granuloma. *National Journal of Maxillofacial Surgery*. 2019 Jan; 10(1):3-7. doi: 10.4103/njms.NJMS_55_18.
- [30] Isaza-Guzman DM, Teller-Carrero CB, Laberry-Bermúdez MP, González-Pérez LV, Tobón-Arroyave SI. Assessment of Clinicopathological Characteristics and Immuno-Expression of COX-2 and IL-10 in Oral Pyogenic Granuloma. *Archives of Oral Biology*. 2012 May; 57(5):503-12. doi: 10.1016/j.archoralbio.2011.11.004.
- [31] Verma PK, Srivastava R, Baranwal HC, Chaturvedi TP, Gautam A, Singh A. Pyogenic Granuloma-Hyperplastic Lesion of the Gingiva. *The Open Dentistry Journal*. 2012 Oct; 6: 153. doi: 10.2174/1874210601206010153.
- [32] Georgoulis A, Zarenti S, Anastasopoulos M, Doufexi AE. Pyogenic Granuloma: A Literature Review and a Case Report. *European Journal of Dental and Oral Health*. 2022 May; 3(3): 1-4.
- [33] Nemoto R, Usui Y, Komatsu H, Tsubota K, Sugawara R, Nagao T et al. Immuno-Phenotypic Profiles in Chalazion and Pyogenic Granuloma Associated with Chalazion. *Graefes Archive for Clinical and Experimental Ophthalmology*. 2024 Apr; 262(4):1329-35. doi: 10.1007/s00417-023-06304-w.
- [34] Krishnan R and Dinesh S. Bacillary Angiomatosis Mimicking Pyogenic Granuloma. *Cureus*. 2023 May; 15(3).
- [35] Salvi GE, Rocuzzo A, Imber JC, Stähli A, Klinge B, Lang NP. *Clinical Periodontal Diagnosis. Periodontology* 2000. 2023 Jul. doi: 10.1111/prd.12487
- [36] Gaw CE, Treat JR, Friedlaender EY, Del Pizzo J. Management of Bleeding Pyogenic Granulomas in Acute Care Settings. *The Journal of Emergency Medicine*. 2022 Sep; 63(3): 339-47. doi: 10.1016/j.jemermed.2022.04.031.
- [37] Kaleeny JD and Janis JE. Pyogenic Granuloma Diagnosis and Management: A Practical Review. *Plastic and Reconstructive Surgery-Global Open*. 2024 Sep; 12(9):e6160. doi: 10.1097/GOX.00000000000006160.
- [38] Zehra F, Al-Tarrak K, Govindan Srinivasan K, McMillan K, Nishikawa H, Hejmadi R et al. A Case of Giant Proliferative Periocular Pyogenic Granuloma. *Orbit*. 2022 May; 41(3):390-1. doi: 10.1080/01676830.2020.1846760.
- [39] Pisano M, Sammartino P, Di Vittorio L, Iandolo A, Caggiano M, Roghi M et al. Use of Diode Laser for Surgical Removal of Pyogenic Granuloma of the Lower Lip in A Pediatric Patient: A Case Report. *The American Journal of Case Reports*. 2021 Jun; 22:e929690-1. doi: 10.12659/AJCR.929690.
- [40] Wu JP, Dong LP, Lu XY, Ge HS, Zhang L, Xiao FL. Treatment of Pyogenic Granuloma in Children with A 595 Nm Pulsed Dye Laser: A Retrospective Study of 212 Patients. *Lasers in Surgery and Medicine*. 2022 Aug; 54(6): 835-40. doi: 10.1002/lsm.23545.