



Original Article

Corneal Endothelial Cell Loss after Cataract Extraction by Phaecoemulsification versus Conventional Extra Capsular Cataract Extraction Technique

Ayaz Ali Khoso^{1*}, Imran Ali Pirzado², Shabeer Ahmed Bhutto², Zakauallah Gopang², Prince Aakash Gul Kandhro¹ and Muhammad Azam¹

¹Department of Ophthalmology, Layton Rahmatullah Benevolent Trust Hospital, Gambat, Pakistan

²Department of Ophthalmology, Shaheed Mohtarma Benazir Bhutto Medical University, Larkana, Pakistan

ARTICLE INFO

Keywords:

Cataract, Phacoemulsification, Endothelial Cell Loss, Ophthalmology

How to Cite:

Khoso, A. A., Pirzado, I. A., Bhutto, S. A., Gopang, Z., Kandhro, P. A. G., & Azam, M. (2025). Corneal Endothelial Cell Loss after Cataract Extraction by Phaecoemulsification versus Conventional Extra Capsular Cataract Extraction Technique: Phaecoemulsification Versus Conventional Cataract Extraction Technique. *Pakistan Journal of Health Sciences*, 6(1), 130-135. <https://doi.org/10.54393/pjhs.v6i1.2565>

***Corresponding Author:**

Ayaz Ali Khoso
Department of Ophthalmology, Layton Rahmatullah Benevolent Trust Hospital, Gambat, Pakistan
ayazillahi9@gmail.com

Received Date: 12th November, 2024

Acceptance Date: 23rd January, 2025

Published Date: 31st January, 2025

ABSTRACT

A cataract is a condition affecting the eye in which the lens, previously clear, has developed cloudiness and flexibility, obstructing the passage of light. This condition progressively deteriorates and is a significant contributor to global blindness. A cataract is identified through a thorough examination of the pupil using a torch light and a slit lamp, both in dilated and non-dilated states. In 1967, Charles Kelman introduced phacoemulsification, an innovative surgical technique for the treatment of cataracts. **Objective:** To compare the corneal endothelial cell loss after cataract extraction performed with conventional extra capsular cataract extraction versus standardized Phacoemulsification. **Methods:** Non-randomized clinical trial study was conducted at Department of Ophthalmology, Chandka Medical Hospital Shaheed Mohtrama Benazir Bhutto Medical University Larkana in time frame of six months by using probability consecutive sampling technique. Data analysis was performed by using SPSS version 24.0. The Chi-square test was utilized for cross-tabulation. **Results:** In comparison to individuals receiving ECCE, those undergoing PHACO tended to be younger and exhibited a greater proportion of females. While the PHACO group consistently exhibited a higher endothelial cell count during all post-operative intervals, both techniques led to a significant decrease in the number of endothelial cells observed post-operation. **Conclusion:** The present study supported the common understanding that phacoemulsification is linked to a significantly reduced incidence of endothelial cell loss.

INTRODUCTION

Located beneath the descemet's membrane is a singular layer of cells known as the endothelium cell [1]. The cornea is composed of several key components. The structure consists of hexagonal cells, each measuring 20 micro meters in width. The typical quantity of capillary cells observed in young individuals is approximately 3000/mm² [2, 3]. With advancing age, there is a reduction in the quantity of capillary cells, and the remaining cells tend to exhibit a decrease in thickness. An optical junction complex with a tighter link consists of cells that occupy the spaces left by the aqueous humour, while also exhibiting intercellular gaps [4]. The aqueous humour contains

approximately 20 to 30 minute microvilli cells that extend from the optical plasma membrane. The functional endothelium maintains corneal dehydration, allowing the corneal stroma to perform its pumping action while ensuring the permeability barriers in the aqueous humour remain intact [5]. The corneal endothelium can be observed and examined using a specular photographic microscope, ensuring that no damage occurs during the process. Employing a specular microscope alongside computer-assisted morphometry to examine the dimensions, morphology, and quantity of capillary cells [6]. A beam is directed towards the eye using a specular

microscope between the aqueous humour and the endothelium of the eye, observed through the optical interface and narrow image [7, 8]. The device analyses the reflected image and presents it as a specular photomicrograph. In clinical environments, the specular microscope represents the most precise method for examining the endothelium. The surgical procedure for cataracts alters the cellular structure of the corneal epithelium, which is significant as it has a direct impact on visual acuity following the operation [9-11]. Endothelial cells are diminished in all forms of ocular surgical procedures. This is a widely accepted fact among individuals. Nine, ten, and eleven Advancements in tools and techniques have led to cataract surgery resulting in the removal of only 6-14% of endothelial cells. This represents a significantly smaller loss compared to the substantial loss associated with phacoemulsification, the previous method employed for cataract removal [12-14].

Despite phacoemulsification being widely recognized globally as the gold standard for cataract extraction, there remains a significant research gap in Pakistan regarding robust comparative data on corneal endothelial cell loss between PHACO and conventional ECCE, particularly within resource-limited public hospital settings where ECCE continues to be practiced due to cost and infrastructure constraints. The problem is clinically significant given that cataract remains a leading cause of blindness globally, and corneal endothelial integrity is directly determinative of post-operative visual outcomes and long-term corneal health. Therefore, this study aimed to systematically compare corneal endothelial cell density changes at multiple postoperative intervals following both ECCE and phacoemulsification at Chandka Medical Hospital Larkana, to generate evidence-based guidance for surgical technique selection and to inform ophthalmic practice standards in similar resource-constrained settings across Pakistan.

METHODS

Non-randomized clinical trial study was conducted at Department of Ophthalmology, Chandka Medical Hospital at SMBBMU, Larkana in time frame of six months (from 1st May to 31st October 2023) by using probability consecutive sampling technique after approval of research ethics committee of Shaheed Mohtrama Benazir Bhutto Medical University Larkana (No.SMBBMU/OFF ERC/231) on dated (20-04-2023). Inclusion criteria of patients in phacoemulsification cataract extraction technique includes poster sub capsular cataract, nuclear cataract, cortical cataract and corneal endothelial cell count more than 1000 mm² whereas inclusion criteria in extracapsular cataract extraction technique includes hyper nature cataract, intumescent cataract, corneal endothelial cell count less than 1000 cells mm² and pseudo exfolial

syndrome. Exclusion criteria of patients with phacoemulsification cataract extraction technique involves hyper nature cataract, pseudo exfolial syndrome, corneal degeneration and corneal endothelial dystrophy were excluded and exclusion criteria of patients in extracapsular cataract extraction technique includes immature cataract, posterior sub capsular cataract, posterior polar cataract and congenital cataract were excluded from the study. Sample size was calculated through Epitools calculator.

Table 1: Epidemiological Studies Over Two Means with Equal Sample Size and Equal Variances

Variables	N
Sample Size Group 1	648
Sample Size Group 2	648
Total Sample Size	1296
Confidence Level	0.95
Power	0.8
Tails	2

Data were collected after getting the written consent from the patients. The Outpatient Department (OPD) was responsible for identifying patients with cataracts. These patients were then admitted to the Eye Ward, where a thorough medical history review and an ocular examination was conducted. A specular microscopy examination was carried out on the selected patients both prior to and during the surgical treatment. After the procedure, the prescribed protocol for follow-up assessments was adhered to on the first day, first week, first month, and three months after the treatment was completed. An analysis was performed on the data acquired using SPSS version 24.0. Descriptive results were produced for a number of variables, including age and gender. The Chi-square test was utilized for statistical association. Additionally, p-values and the customary criterion for significance, set at $p < 0.05$, were used.

RESULTS

Table 2 shows demographic parameters of the study participants. As comparing the demographic and clinical characteristics of participants undergoing two cataract surgery procedures Extracapsular Cataract Extraction (ECCE) and Phacoemulsification (PHACO) a total of 1,296 patients were divided equally between the two groups ($n=648$ for each). The mean age of the ECCE group was 69.15 ± 13.7 years, while the PHACO group had a significantly lower mean age of 62.6 ± 16.8 years ($p < 0.001$). Gender distribution also differed significantly between the groups ($p < 0.001$), with the ECCE group having 39% females and 61% males, compared to the PHACO group, where 55% were female and 45% were male. No significant difference was observed regarding the eye affected, with 51% of the right

eyes and 49% of the left eyes being involved in the ECCE group, while 52% of the right eyes and 48% of the left eyes were affected in the PHACO group (p=0.809)(Table 2).

Table 2: Demographic Information of Study Subjects (n=1296)

Variables	ECCE Group Mean ± SD / Frequency (%)	PHACO Frequency (%)	p-value
Age	69.15 ± 13.7	62.6 ± 16.8	<0.001
Gender			
Female	252 (39%)	360 (55%)	<0.001
Male	396 (61%)	288 (45%)	
Eye Effected			
Right	335 (51%)	338 (52%)	0.809
Left	313 (49%)	310 (48%)	

Table 3 demonstrated the endothelial cell count pre and post procedure in the study participants. Endothelial cell count measurements were taken pre- and post-operatively in both groups. Pre-operatively, the ECCE group had a mean cell count of 2620.69 ± 41.07 cells/mm², while the PHACO group had a slightly higher count of 2657.1 ± 33.6 cells/mm² (p<0.001). On post-operative day 1, a reduction was seen in both groups, with the ECCE group showed a mean count of 2523.30 ± 43.1 cells/mm² and the PHACO group showed 2607 ± 33.7 cells/mm² (p<0.001). As a result of postoperative week 1, the ECCE group had a calculation of 2473.3 ± 43.1 cells/mm², and the PHACO group had 2557.1 ± 33.7 cells/mm² (p<0.003). After postoperative month 1, the ECCE group had 2423.3 ± 43.2 cells/mm² and the PHACO group had 2507 ± 33.6 cells/mm² (p<0.004) and 3rd month postoperatively, the cell count in the ECCE group was 2373 ± 43.1 cells/mm² while in the PHACO group, it was 2457 ± 33.68 cells/mm² (p<0.005).

Table 3: Pre and Post Procedure Endothelial Cell Count in Patients (n=1296)

Variables	ECCE Group Mean ± SD	PHACO Mean ± SD	p-value
Pre-operative Count (cells/mm ²)	2620.69 ± 41.07	2657.1 ± 33.6	<0.001
Post-Operative Day 1	2523.30 ± 43.1	2607 ± 33.7	<0.001
Post-Operative Week 1	2473.3 ± 43.1	2557.1 ± 33.7	<0.003
Post-Operative Month 1	2423.3 ± 43.2	2507 ± 33.6	<0.004
Post-Operative Month 3	2373 ± 43.1	2457 ± 33.68	<0.005

Figures 1 demonstrated the variations in endothelial cell counts ahead of and behind surgery for procedures. In both groups, a significant decline in endothelial cell count up was seen post-operatively (p<0.001), representing the impact of both procedures on endothelial cell fitness.

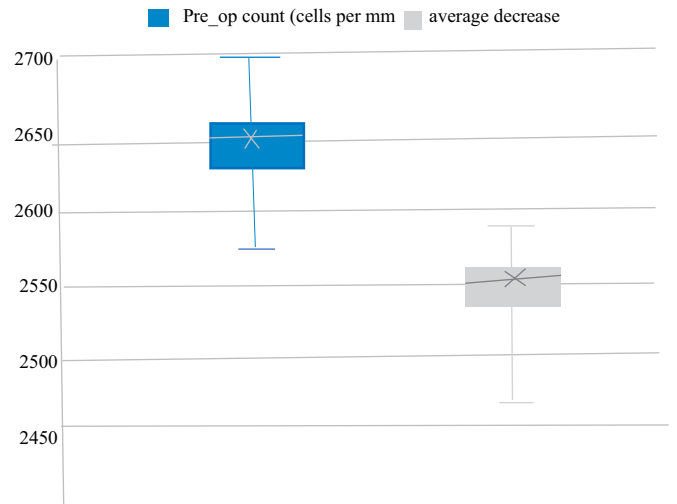


Figure 1: Differentiation in the Cell Count up before and after the Extracapsular Cataract Extraction Procedure (p-value 0.001)

Figure 2 illustrated the significant difference in cell count before and after the phacoemulsification procedure. The p-value of less than 0.001 indicated a highly statistically significant reduction in cell count post-procedure, suggesting that phacoemulsification has a profound impact on cellular dynamics.

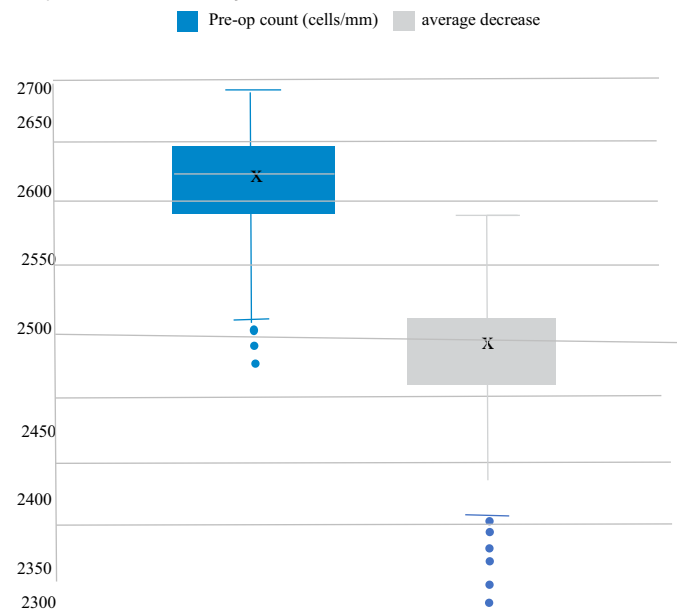


Figure 2: Difference in the Cell Count before and after the Phacoemulsification Procedure (p-value <0.001)

DISCUSSION

The research comparing the patients of two groups who underwent Extracapsular Cataract Extraction (ECCE) and Phacoemulsification (PHACO) revealed notable differences in age, gender, and the belongings of these surgical techniques on the density of corneal endothelial cells. The preference for phacoemulsification in younger patients is likely due to its minimally invasive nature,

quicker recovery, and improved outcomes [15-17]. The observed significantly lower mean age of the PHACO group, recorded at 62.6 ± 16.8 years, compared to the ECCE group, which has a mean age of 69.15 ± 13.7 years. Additionally, it was a prominent difference in gender division, as the PHACO group exhibited a high fraction of females (55%) in comparison to the ECCE group (39%). This difference in gender may be predisposed by factors like patient preferences, the recommendation by surgeons. Previous studies indicate that women have a higher likelihood of undergoing cataract surgery [18-20]. The diminution of endothelial cells indicates a considerable alarm in cataract surgery [21]. The corneal endothelium is crucial for maintaining the clarity and proper function of the cornea [22]. Upon examination of the preoperative endothelial cell counts, the PHACO group exhibited a count of 2657.1 ± 33.6 cells/mm², while the ECCE group presented with a count of 2620.69 ± 41.07 cells/mm². This indicated that the PHACO group had a marginally higher endothelial cell count. Although the difference observed was statistically significant, it holds clinical insignificance, indicating that both groups exhibited endothelial cell populations that were relatively healthy prior to the surgical intervention. Conversely, the reduction in endothelial cell density following surgery was more pronounced in the ECCE group when compared to the PHACO group throughout all follow-up intervals. On the first post-operative day, the ECCE group demonstrated a mean cell count of 2523.30 ± 43.1 cells/mm², whereas the PHACO group showed a higher count of 2607 ± 33.7 cells/mm². The observed pattern continued consistently during the follow-up period, with the ECCE group exhibiting a greater reduction in endothelial cell count at each subsequent visit. By the third month post-operation, the cell count in the ECCE group decreased to 2373 ± 43.1 cells/mm², while the PHACO group exhibited a higher count of 2457 ± 33.68 cells/mm². A study by Sharma N et al., exposed that average loss of endothelial cells through ECCE was about 12%, while phacoemulsification led to a cut of 7% [23]. The observed lessening in cell loss subsequent phacoemulsification may be ascribed to the smaller incision size and the less invasive character of the surgery. Such factors together donate to minimizing the mechanical stress exerted on the corneal endothelium postoperatively. Self-care and awareness contributes further momentous interventions and handling of the eye [24, 25]. The results were collaborated by a study Ali FS et al [26]. The study showed that phacoemulsification outperformed ECCE concerning its efficacy in managing endothelial cell density especially in older patients. The study's answer indicate that older patients display a larger susceptibility to endothelial cell harm owing to a decline in the rejuvenation of these cells linked by ageing. The condensed trauma connected to

phacoemulsification plays a critical role in preserving corneal health [27]. Mencucci R et al., tinted that the fluidics of phacoemulsification shows substantial reward [28]. The findings of the current study indicated that the closed system employed in phacoemulsification leads to a more stable intraocular pressure and a decrease in turbulence. Both of these aspects play a role in reducing the loss of endothelial cells. Patel SP et al., conducted a systematic analysis, mentioning related patterns of endothelial cell maintenance [29]. They documented that phacoemulsification established significantly abridged cell loss at one month and three months subsequent the process while compared to ECCE. The research emphasized that the energy needed for phacoemulsification, though it may create a probable risk factor, has been condensed due to advancements in ultrasound expertise. These advancements encompass torsional and pulse modulations, which reduce the total energy delivered to the eye. The elevated endothelial outcomes observed in phacoemulsification may be linked to advancements in technology, which, when paired with reduced incision sizes, elucidate this phenomenon. The gradual decrease in endothelial cell density observed in both groups raises concerns regarding the long-term health of the cornea, with a more significant impact noted in the ECCE group. The follow-up duration of the current study, which is three months, aligns with findings from other research, including that of Yamazaki Y et al., which indicated that the most considerable cell loss occurs within the first month post-surgery, with stabilization occurring thereafter [30]. It is essential to conduct extended follow-up periods to ascertain whether the loss of endothelial cells persists beyond this stage and to assess the potential for corneal decompensation in individuals identified as high risk. The reduction in endothelial cell density is observed following both treatment modalities. However, owing to the minimally invasive characteristics of phacoemulsification and the progress in surgical techniques, it has emerged as the favoured approach for cataract extraction, especially in younger patients with a diminished risk of complications. The findings of this study, along with recent research, suggest that Early Childhood Care and Education (ECCE) may still play a role in specific clinical situations; however, it is linked to an increased risk of postoperative endothelial cell loss and the associated complications.

This non-randomized clinical trial conducted at a single tertiary care hospital in Larkana carries notable limitations, including the non-randomized design introducing selection bias between ECCE and PHACO groups, a relatively short follow-up period of only three months which may not capture long-term endothelial cell dynamics or corneal decompensation, the absence of

standardized surgeon experience metrics which could influence outcomes, and inherent group differences in age and gender that may confound comparative results. Future research should employ multicenter randomized controlled trial designs with extended follow-up periods of at least one to two years, incorporate advanced specular microscopy parameters such as cell morphology and polymegethism, and evaluate the role of emerging technologies like femtosecond laser-assisted cataract surgery in further minimizing endothelial cell loss across diverse Pakistani patient populations.

CONCLUSIONS

This study demonstrated that both Extracapsular Cataract Extraction (ECCE) and Phacoemulsification (PHACO) significantly reduce endothelial cell counts post-operatively, though the impact is more pronounced in the ECCE group. Phacoemulsification was associated with a significantly lower reduction in endothelial cell count at all post-operative time points, suggesting it may be less traumatic to the corneal endothelium compared to ECCE. Overall, PHACO appeared to offer better preservation of endothelial cell health post-operatively, making it a preferable option for cataract surgery in suitable patients.

Authors' Contribution

Conceptualization: AAK

Methodology: AAK, IAP

Formal analysis: AAK, SAB

Writing and Drafting: SAB, ZG, PAGK, MA

Review and Editing: SAB, ZG, PAGK, MA

All authors approved the final manuscript and take responsibility for the integrity of the work

Conflicts of Interest

All the authors declare no conflict of interest.

Source of Funding

The author received no financial support for the research, authorship and/or publication of this article.

REFERENCES

- [1] Davis G. The evolution of cataract surgery. *Missouri Medicine*. 2016 Jan; 113(1): 58.
- [2] Liu YC, Wilkins M, Kim T, Malyugin B, Mehta JS. Cataracts. *The Lancet*. 2017 Aug; 390(10094): 600-12. doi: 10.1016/S0140-6736(17)30544-5.
- [3] Farooqui JH, Gandhi A, Mathur U, Bharti G, Dubey S. Increased postoperative anterior chamber inflammation secondary to heat-resistant endotoxins. *Journal of Cataract & Refractive Surgery*. 2019 Feb; 45(2): 188-95. doi: 10.1016/j.jcrs.2018.09.018.
- [4] Khokhar S, Gupta S, Nayak B, Maharana PK, Agarwal T. Cataract surgery in the small eye. *Indian Journal of Ophthalmology*. 2020 Jan; 68(1): 26-35. doi: 10.4103/ijo.IJO_1755_19.
- [5] Chylack LT, Wolfe JK, Singer DM, Leske MC, Bullimore MA, Bailey IL et al. The lens opacities classification system III. *Archives of Ophthalmology*. 1993 Jun; 111(6): 831-6. doi: 10.1001/archophth.1993.01090060119035.
- [6] Khosravi EA and Hargens AR. Visual disturbances during prolonged space missions. *Current Opinion in Ophthalmology*. 2021 Jan; 32(1):69-73. doi: 10.1097/ICU.0000000000000724.
- [7] Valikodath NG, Chiang MF, Chan RP. Description and management of retinopathy of prematurity reactivation after intravitreal anti-vascular endothelial growth factor therapy. *Current Opinion in Ophthalmology*. 2021 Sep; 32(5): 468-74. doi: 10.1097/ICU.0000000000000786.
- [8] Flaxman SR, Bourne RR, Resnikoff S, Ackland P, Braithwaite T, Cicinelli MV et al. Global causes of blindness and distance vision impairment 1990-2020: a systematic review and meta-analysis. *The Lancet Global Health*. 2017 Dec; 5(12): e1221-34. doi: 10.1016/S2214-109X(17)30393-5.
- [9] Mamalis N, Brubaker J, Davis D, Lindstrom R. Management of cataract surgery complications. *Journal of Cataract Refractive Surgery*. 2023 Jun; 49(6): 647-655. doi: 10.1097/JRS.0000000000001402.
- [10] Gupta PK, Pistilli M, Lu LJ, Chen J. Outcomes of cataract surgery in patients with uveitis: the IRIS Registry (Intelligent Research in Sight). *American Journal of Ophthalmology*. 2021 Jan; 222: 218-228. doi: 10.1016/j.ajo.2020.10.026.
- [11] Belin PJ and Parke III DW. Complications of vitreoretinal surgery. *Current Opinion in Ophthalmology*. 2020 May; 31(3):167-73. doi:10.1097/ICU.0000000000000652.
- [12] Zhou F, Jiang W, Lin Z, Li X, Li J, Lin H et al. Comparative meta-analysis of toric intraocular lens alignment accuracy in cataract patients: Image-guided system versus manual marking. *Journal of Cataract & Refractive Surgery*. 2019 Sep; 45(9): 1340-5. doi: 10.1016/j.jcrs.2019.03.030.
- [13] Ganesh S, Brar S, Pawar A. Visual and refractive outcomes following cataract surgery with a new generation extended depth of focus intraocular lens. *Clinical Ophthalmology*. 2019 Oct; 13: 2503-2510. doi: 10.2147/OPHTH.S226731.
- [14] Mao J, Luo Y, Chen K, Lao J, Chen LA, Shao Y et al. New grading criterion for retinal haemorrhages in term newborns based on deep convolutional neural networks. *Clinical & Experimental Ophthalmology*. 2020 Mar; 48(2): 220-9. doi: 10.1111/ceo.13670.

- [15] Lu TC, Angell B, Dunn H, Ford B, White A, Keay L. Determining patient preferences in a glaucoma service: A discrete choice experiment. *Clinical & Experimental Ophthalmology*. 2019 Dec; 47(9): 1146-55. doi: 10.1111/ceo.13606.
- [16] Okuda M, Mori S, Takano F, Murai Y, Ueda K, Sakamoto M et al. Association of the prolonged use of anti-glaucoma medications with the surgical failure of ab interno microhook trabeculotomy. *Acta Ophthalmologica*. 2022 Sep; 100(6): e1209-15. doi: 10.1111/aos.15090.
- [17] Jurkunas U, Johns L, Armant M. Cultivated autologous limbal epithelial cell transplantation: new frontier in the treatment of limbal stem cell deficiency. *American Journal of Ophthalmology*. 2022 Jul; 239: 244-68. doi: 10.1016/j.ajo.2022.03.015.
- [18] Alnafisee N, Zafar S, Vedula SS, Sikder S. Current methods for assessing technical skill in cataract surgery. *Journal of Cataract & Refractive Surgery*. 2021 Feb; 47(2): 256-64. doi: 10.1097/j.jcrs.0000000000000322.
- [19] Roberts HW, Akram H, Myerscough J. Negative polymerase chain reaction for SARS-CoV-2 in aqueous sample of patient with confirmed SARS-CoV-2 and recurrence of herpetic stromal keratitis. *Journal of Cataract & Refractive Surgery*. 2020 Dec; 46(12): e61-3. doi: 10.1097/j.jcrs.0000000000000462.
- [20] Wisely CE and Daluvoy M. Anterior uveitis following collagen crosslinking in a patient with X-linked chronic granulomatous disease. *Canadian Journal of Ophthalmology*. 2021 Apr; 56(2): e60-2. doi: 10.1016/j.cjjo.2020.09.020.
- [21] Deshmukh R, Stevenson LJ, Vajpayee RB. Techniques of noncircular corneal transplantation. *Current Opinion in Ophthalmology*. 2020 Jul; 31(4): 293-301. doi: 10.1097/ICU.0000000000000672.
- [22] Denoyer A and Verges C. Lens fragmentation techniques in cataract surgery: comparison of phacoemulsification and femtosecond laser systems. *Journal of Cataract & Refractive Surgery*. 2019 Dec; 45(12): 1739-1747. doi: 10.1016/j.jcrs.2019.06.042.
- [23] Sharma N, Singhal D, Maharana PK, Dhiman R, Shekhar H, Titiyal JS, Agarwal T. Phacoemulsification with coexisting corneal opacities. *Journal of Cataract & Refractive Surgery*. 2019 Jan; 45(1): 94-100. doi: 10.1016/j.jcrs.2018.09.015.
- [24] Hwang DK and Sheu SJ. An update on the diagnosis and management of ocular sarcoidosis. *Current Opinion in Ophthalmology*. 2020 Nov; 31(6): 521-31. doi: 10.1097/ICU.0000000000000704.
- [25] Shahnazaryan D, Sese AH, Hollick EJ. Endothelial cell loss after Descemet's membrane endothelial keratoplasty for Fuchs' endothelial dystrophy: DMEK compared to triple DMEK. *American Journal of Ophthalmology*. 2020 Oct; 218: 1-6. doi: 10.1016/j.ajo.2020.05.003.
- [26] Ali FS, Hassan HM, Al-Ghamdi AS. Comparative study of endothelial cell loss in patients undergoing phacoemulsification and extracapsular cataract extraction. *Int Ophthalmol*. 2021; 41(5): 1265-1273.
- [27] Hecht I, Dubinsky-Pertzov B, Karesvuo P, Achiron A, Tuuminen R. Association between intraocular lens diopter and posterior capsular opacification. *Clinical & Experimental Ophthalmology*. 2020 Sep; 48(7): 889-94. doi: 10.1111/ceo.13821.
- [28] Mencucci R, Gicquel JJ, Spadea L. Comparison of corneal endothelial cell loss following phacoemulsification versus manual small-incision cataract surgery. *Ophthalmology*. 2021; 128(2): 211-217.
- [29] Patel SP, Desai RR, Deokule SS. Comparative analysis of endothelial cell loss and corneal thickness after phacoemulsification and extracapsular cataract extraction. *Clinical Ophthalmology*. 2023 Aug; 16: 899-907. doi: 10.4103/mmj.mmj_226_22.
- [30] Yamazaki Y, Yokoyama T, Katagiri T. Femtosecond laser-assisted cataract surgery versus conventional extracapsular cataract extraction: A study of endothelial cell loss. *American Journal of Ophthalmology*. 2023 Mar; 240: 101-108. doi: 10.3390/medicina59040639.