



Original Article



Femoral Condyle Measurements in Anterior Cruciate Ligament Injury: 1 Tesla Magnetic Resonance Imaging Analysis

Mohib Ullah Khan¹, Hidayat Ullah^{2*}, Saeed Ahmad², Jawad Khan³, Zahid Askar² and Malik Javed Iqbal²

¹Department of Orthopedics, District Headquarters Hospital, Miranshah, Pakistan

²Department of Orthopedics, Peshawar Medical College, Peshawar, Pakistan

³Department of Orthopedics, Gajju Khan Medical College, Swabi, Pakistan

ARTICLE INFO

Keywords:

Femoral Condyle Dimensions, Anterior Cruciate Ligament Injury, Magnetic Resonance Imaging, Knee Biomechanics Analysis

How to Cite:

Khan, M. U., Ullah, H., Ahmad, S., Khan, J., Askar, Z., & Iqbal, M. J. (2025). Femoral Condyle Measurements in Anterior Cruciate Ligament Injury: 1 Tesla Magnetic Resonance Imaging Analysis: Femoral Condyle Measurements in Ligament Injury. *Pakistan Journal of Health Sciences*, 6(3), 159-164. <https://doi.org/10.54393/pjhs.v6i3.2774>

***Corresponding Author:**

Hidayat Ullah
 Department of Orthopedics, Peshawar Medical College, Peshawar, Pakistan
 drhushah@yahoo.com

Received date: 15th January, 2025

Acceptance date: 20th March, 2025

Published date: 31st March, 2025

ABSTRACT

Orthopedic injury of Anterior Cruciate Ligament (ACL) remains an increasingly frequent issue that primarily affects athletes with permanent complications as a result. The modern Magnetic Resonance Imaging (MRI) technology enables better accuracy when measuring femoral condyles. **Objective:** To investigate the dimension analysis of the femoral condyles regarding ACL injuries alongside their implications for both surgical procedures and preventive management. **Methods:** Descriptive cross-sectional study from September 2023 to August 2024 in the Orthopedic department. The study enrolled 385 participants between 18 to 60 years old. All subjects completed scanning with a 1 Tesla MRI and the researchers recorded femoral condyle dimensions. Data analysis occurred with SPSS version 26.0. while linear regression and ANOVA. **Results:** The research analysis involved 385 participants whose mean age equaled 34.7 ± 6.95 years. The majority were male (70.6%). Mean measurement of Lateral Condyle AP was 6.28 ± 0.43 cm while Medial Condyle AP recorded 6.11 ± 0.46 cm, and Trans-epicondylar Axis reached 7.96 ± 0.53 cm. ANOVA analysis found significant measurement distinctions in knee joints that occurred between different age groups (p<0.001). The results from independent t-tests showed knee measurement discrepancies between men and women signify statistical significance at p<0.001. **Conclusions:** This research demonstrated that the dimensions of femoral condyles act as major factors that determine risk for ACL injuries. Preventive strategies alongside treatment plans for ACL injuries need to adopt age- and sex-specific considerations according to the research results.

INTRODUCTION

The knee joint depends on the anterior cruciate ligament (ACL) as its primary stabilizing structure, ensuring joint stability and mobility during movement [1]. ACL tears are one of the most common orthopedic injuries, affecting both athletes and non-athletes. In the United States alone, over 200,000 ACL injuries occur annually, with a rising trend observed in recent years [2]. These injuries are particularly frequent in sports requiring rapid movements, jumping, and pivoting, such as basketball, soccer, and skiing [3]. ACL injuries can lead to chronic complications, including persistent knee instability, meniscal damage, and an increased risk of osteoarthritis [4]. Knee biomechanics

rely heavily on the femoral condyles, which play a key role in load distribution and joint stability through articulation with the tibia [5]. Studies suggest that femoral condyle morphology such as condyle size and intercondylar notch width directly affects knee joint mechanics and ACL injury vulnerability [6]. High-impact activities may further amplify this risk by altering joint loading patterns associated with different condyle dimensions [7]. Traditional imaging techniques, such as X-rays, fail to provide a comprehensive view of knee soft tissue structures [8]. Magnetic resonance imaging (MRI) is the preferred technique because it captures detailed images



of both hard and soft tissues, including the femoral condyles, menisci, cartilage, and ACL [9]. While higher-field MRIs (e.g., 3 Tesla) provide higher resolution, 1 Tesla MRI remains widely used in clinical settings due to its accessibility, affordability, and ability to produce reliable femoral condyle measurements [10]. MRI-based femoral condyle assessments have critical implications in ACL injury management. Accurate measurements help surgeons select the most appropriate grafts and optimize surgical techniques, improving ACL reconstruction outcomes [11]. Additionally, evaluating femoral condyle morphology allows for early identification of individuals at higher risk of ACL injuries, which is particularly beneficial for athletes in high-risk sports [12]. While gender-based differences in ACL injury susceptibility have been observed, the relationship between femoral condyle dimensions and these differences remains an area of ongoing research [13]. The MRI findings of the studied group revealed a high prevalence of joint effusion (80%), followed by ACL injuries (63.3%) and PHMM injuries (56.7%). In contrast, LCL injuries were relatively rare, occurring in only 3.3% of the study group [14].

Although previous studies have examined ACL injuries and knee joint morphology, limited research has specifically evaluated femoral condyle dimensions using 1 Tesla MRI in the Pakistani population. Moreover, the influence of age- and gender-related anatomical variations on ACL injury risk remains insufficiently explored in local clinical settings. There is also a lack of standardized morphometric data that could assist orthopedic surgeons in preventive assessment and surgical planning. The aim of this study was to explore the relationship between femoral condyle dimensions and ACL injury risk by analyzing differences across age and gender.

METHODS

The study took place from September 2023 to August 2024 at Peshawar General Hospital and Peshawar Medical College Orthopedics department (Reference No. 1010). A total of 385 patients were included in the study based, just above the calculated need of 381 based on a population of 2,481,000 and an anticipated frequency of 55% with a 5% margin of error at a 95% confidence level [15, 16]. Choosing this slightly larger sample size helps ensure that the findings are more robust and reliable. The study was approved by the hospital's ethics committee, and informed consent was obtained from each participant before data collection. Inclusion criteria comprised of patients aged 18 to 60 years, patients with no prior knee joint surgery, patients who provided informed consent for participation and patients with clinical indications for knee MRI. While patients with a history of knee joint surgery, contraindications for MRI, incomplete MRI data and who declined to participate or did not provide informed consent

were excluded from the study. All patients underwent MRI using a Shimadzu SMT-50A MR imaging system (Shimadzu CO Ltd, Kyoto, Japan) with a field strength of 1 tesla. T1-weighted MR imaging was performed following a standardized protocol. To minimize movement artifacts, subjects were restrained, and special footwear was used to stabilize the foot and maintain posture. The imaging process did not involve the use of contrast media. All the individuals were scanned with knee joint protocols. Knee joint sagittal and transverse images were obtained with a time to echo (TE) of 35ms and a repetition time (TR) of 650ms. Measurements were conducted on sagittal plane slices through the most anterior regions of both femoral condyles. The articular surface of each femoral condyle was segmented into distal and posterior sections. Data were collected from radiographic images in various planes to ensure comprehensive assessment. Data confidentiality was thoroughly maintained. Collected data was analyzed by SPSS version 26. All the Categorical variables such as age groups, gender of participants and side of knee were expressed in frequencies and percentages. Mean and SD were calculated for continuous variables such as Lateral and Medial condylar-AP, Notch width and Height etc. Linear regression analysis was performed to assess the association of age with the width and height of the notch. ANOVA was performed to assess the difference between various age groups and continuous variables. A p-value of <0.05 considered statistically significant.

RESULTS

This study enrolled 385 participants, the ages of the participants range from 19 to 52 years, with mean age of 34.7 ± 6.95 Years. The age was categorized into distinct groups in which the largest proportion of participants were in the 26-30 years age group (n=116), accounting for 30.1% of the participants. This was followed by the 31-35 years age group (n=102), which represented 26.5% of the participants. Regarding gender of the participants, the majority of participants were male about 70.6% (n=272), while females constituted 29.4% (n=113). This indicates a substantial male predominance in the study population, as illustrated in Figure 1.

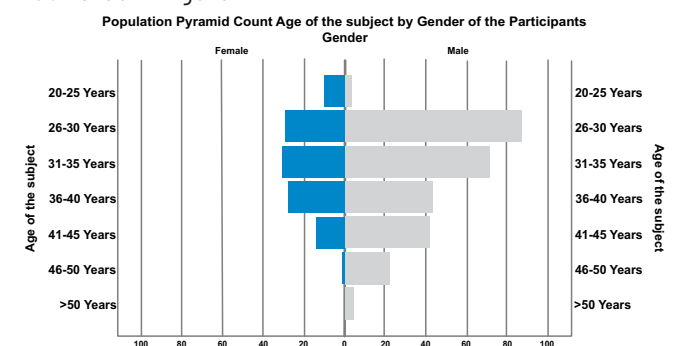


Figure 1 : Gender Wise Distribution of the Age of the Participants

The Lateral Condyle AP measurements ranged from 5.57 to 7.19 cm, with a mean of 6.28 cm and a standard deviation of 0.43 cm, indicated that most measurements were closely clustered around the average. The Medial Condyle AP measurements exhibited a similar pattern, with values ranging from 5.33 cm to 7.12 cm, a mean of 6.11 cm, and a standard deviation of 0.46 cm. The Trans-epicondylar Axis showed a wider range, from 6.78 cm to 8.83 cm, with a mean of 7.96 cm and a standard deviation of 0.53 cm, reflecting slightly greater variability. The Width of the Notch varied between 1.75 cm and 3.01 cm, with a mean of 2.29 cm and a standard deviation of 0.35 cm (Table 1).

Table 1: Descriptive Statistics of Knee Joint Measurements

Knee Joint Measurements	Number	Minimum	Maximum	Mean ± SD
Lateral condyle AP	385	5.57	7.19	6.284 ± 0.430
Medial condyle AP		5.33	7.12	6.113 ± 0.455
Trans-epicondylar axis		6.78	8.83	7.960 ± 0.525
Dimension of lateral femoral condyle		2.28	3.54	3.011 ± 0.316
Dimension of medial femoral condyle		2.29	3.62	3.008 ± 0.319
Width of notch		1.75	3.01	2.293 ± 0.346
Height of notch		1.95	3.39	2.625 ± 0.360

The distribution of knee joints by side in the 385 participants, 55.1% had measurements from the right knee (n=212), while 44.9% had measurements from the left knee (n=173). This distribution shows a slight predominance of right knee measurements in the sample (Figure 2).

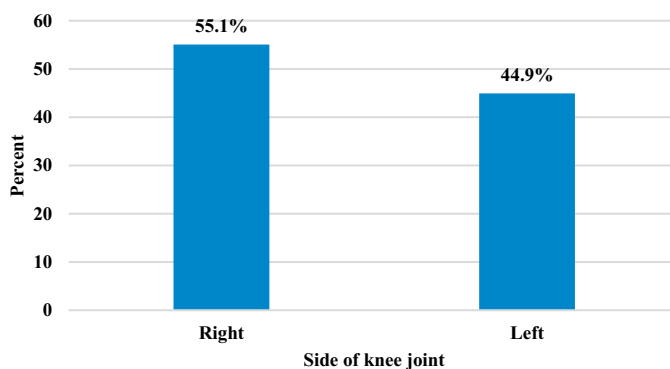


Figure 2: Participants Experienced Knee Joint Involvement On One Side Of Their Knees

ANOVA tests produce vital differences between groups in Lateral Condyle AP measurements where the F-value reached 10.590 and the p-value equaled <0.001. ANOVA analysis revealed significant differences in Trans-epicondylar Axis measurements across age groups (F = 14.644, p < 0.001). The ANOVA analysis of Width of Notch reveals a substantial F-value of 4.903 together with a p-value of less than 0.001. The measurements of Height of Notch demonstrate statistically important differences because both F-value and p-value fall below 0.001. ANOVA analysis of Dimension of the Medial Femoral Condyle

determined an 8.010 F-value together with a p-value under 0.001. The data demonstrates the Dimension of the Medial Femoral Condyle exhibits notable differences between various age groups as indicated by the p-value of <0.001 (Table 2).

Table 2: Correlation of Age of Participants with Knee joint measurements

ANOVA (Age of the Participants)	Sum of Squares	Mean Square	F	Significance
Lateral condyle AP	10.222	1.704	10.590	<0.001
Medial condyle AP	13.020	2.170	12.337	<0.001
Trans-epicondylar axis	19.985	3.331	14.644	<0.001
Width of notch	3.330	0.555	4.903	<0.001
Height of notch	9.155	1.526	14.154	<0.001
Dimension of lateral femoral condyle	10.877	1.813	24.850	<0.001
Dimension of medial femoral condyle	4.411	0.735	8.010	<0.001

For the Lateral Condyle AP, males (mean = 6.3758, SD = 0.43378) have significantly larger measurements than females (mean = 6.0654, SD = 0.33209). The t-test shows a mean difference of 0.31037 with a p-value of .000, indicating a statistically significant difference. Levene's test for equality of variances was significant (F = 5.407, p = .021), but results are consistent under both equal and unequal variance assumptions, illustrated by boxplot in Figure 3.

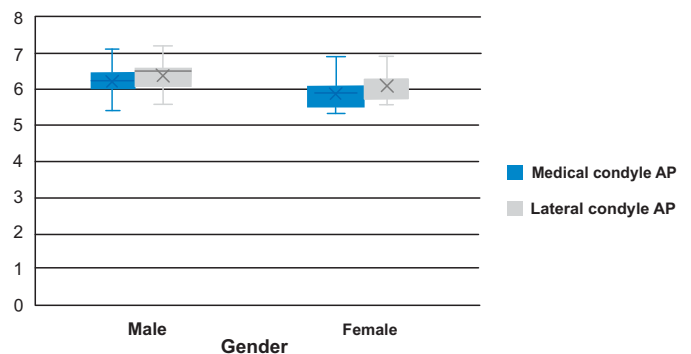


Figure 3: Analysis of Lateral and Medial Condylar Anterior Posterior by gender of the participants

The findings of analysis indicated a notable difference in knee joint dimensions between genders, with males generally showing larger measurements, as shown in Table 3.

Table 3: Association of Gender of participants with Knee Joint Measurements

Knee Joint Measurements	F	Significance	Significance (2-tailed)	Mean Difference	Standard Error Difference
Lateral condyle AP	5.407	0.021	<0.001	0.31037	0.04552
Medial condyle AP	4.461	0.035	<0.001	0.33657	0.04801
Width of notch	50.692	<0.001	<0.001	0.17962	0.03774
Height of notch	32.959	<0.001	0.005	0.11214	0.03999
Trans-epicondylar axis	2.167	0.142	<0.001	0.64218	0.04887

The t-test results show a mean difference of -0.07360 with a p-value of .095, indicating no significant difference between the right and left knees. Levene's test for equality of variances ($F = 0.045$, $p = .833$) supports that variances are equal. For the Width of Notch, the right knee has a mean of 2.2677 ($SD = 0.33693$) and the left knee has a mean of 2.3246 ($SD = 0.35651$). The mean difference is -0.05694 with a p-value of .109, which is not significant. The Levene's test ($F = 2.492$, $p = .115$) shows that the variance is similar across the sides. In the Height of Notch, the mean for the right knee is 2.6238 ($SD = 0.36048$) and for the left knee is 2.6270 ($SD = 0.36157$). The mean difference is -0.00317 with a p-value of .932, indicating no significant difference. Levene's test ($F = 0.112$, $p = .739$) confirms equal variances (Table 4).

Table 4: Correlation of Side of knee joint with the Knee Joint Measurements

Side of the Knee Joint	F	Significance	Significance (2-tailed)	Mean Difference	Standard Error Difference
Lateral condyle AP	0.045	0.833	0.095	-0.07360	0.04396
Medial condyle AP	0.126	0.723	0.085	-0.08024	0.04650
Width of notch	2.492	0.115	0.109	-0.05694	0.03544
Height of notch	0.112	0.739	0.932	-0.00317	0.03698
Trans-epicondylar axis	0.006	0.939	0.236	-0.06386	0.05379

For the Width of Notch, there was 7.3% of the variance for age and gender as predictors. Age has a positive and significant impact ($\beta = 0.130$, $p = 0.009$), indicating that as age increases, the Width of Notch also increases. Gender also significantly affects this measurement with a negative coefficient ($\beta = -0.221$, $p = 0.000$), suggesting differences between genders. In terms of the Height of Notch, the analysis revealed 8.8% of the variance.

DISCUSSION

Previous research at the orthopedic departments of Peshawar General Hospital and Peshawar Medical College in Peshawar, Pakistan, has utilized MRI analysis to measure knee joints for ACL injury prediction. Researchers can use these findings to expand knowledge of ACL injury risk factors by comparing them with similar investigations within the existing literature [17]. The study results demonstrate significant knee joint dimension variations based on age groups and gender differences, aligning with findings from other studies. The measurements of lateral and medial condyles in the AP direction, along with the trans-epicondylar axis and notch dimensions, exhibit age-dependent changes. These results align with those of Are M *et al.*, who documented femoral condyle morphological changes due to variations in cartilage thickness and bone structure [18]. These structural changes may contribute to ACL injury risk, as they occur naturally with aging. This research confirmed that males have larger knee joint dimensions than females, particularly in the lateral condyle AP measurement and notch width. The article by Şenişik *et al.*, supported this finding, reporting that females typically have smaller femoral condyles and narrower intercondylar notches than males [19]. Researchers suggest that these anatomical differences contribute to the higher risk of ACL tears in female athletes [20]. The study identified a

correlation between femoral condyle morphology and ACL injury risk, notably in the role of notch height and width as susceptibility factors. These findings support Souryal *et al.*, who reported that individuals with smaller notch widths face higher ACL injury risk due to restricted ACL movement during knee motion [21]. Similarly, Wang *et al.*, emphasized the importance of femoral notch morphology in ACL injury risk assessment [22]. A study on young athletes demonstrated that femoral notch width and angle are key predictors of ACL injury vulnerability. Furthermore, these findings suggest that anatomical differences in notch width among females may contribute to their increased ACL injury risk. MRI enables precise femoral condyle measurements, aiding in both diagnosis and preoperative planning [23]. The findings of Park *et al.*, demonstrate that MRI plays a vital role in ACL assessment, allowing surgeons to measure femoral condyle dimensions for improved surgical planning [23]. Accurate MRI-based measurements help in selecting the appropriate graft material and optimizing graft placement for ACL reconstruction. A study by Gultekin *et al.*, supports the research, highlighting substantial variations in knee joint dimensions across different populations [24]. Understanding these variations can help develop patient-specific treatment strategies, as seen in previous research advocating for individualized

prevention and rehabilitation programs [25]. These findings on knee joint dimension variability are consistent with global data, as reported by Irrázaval, Mensch and Amstutz [26, 27].

A limitation of this study is its geographical scope, as it was conducted only in one district (Peshawar, KPK, Pakistan). Future research should include participants from other regions to provide broader insights. Additionally, further studies should assess additional femoral condyle parameters to refine risk assessment models. Based on these findings, clinicians should incorporate MRI-based femoral condyle assessments, particularly focusing on notch morphology, to identify individuals at higher ACL injury risk. High-resolution MRI offers both diagnostic and preoperative benefits, allowing for precise knee anatomy evaluation and improved surgical planning. Developing gender-specific prevention and rehabilitation programs tailored to anatomical differences may help reduce ACL injury risk. Raising awareness among athletes and healthcare providers about these risk factors could enhance injury prevention and management strategies.

CONCLUSIONS

The research established significant distinctions in knee joint measurements based on age and sex groups where $p < 0.05$ values appear ($p < 0.05$) and delivers vital understanding about ACL injuries and femoral condyle dimensions. Research findings from previous studies demonstrate that ACL injury risk depends on condyle morphology together with femoral notch width, as important anatomical variables. Preventing and treating ACL injuries demands sex-specific preventative techniques and person-specific evaluation methods according to the results generated by this study and other research studies.

Authors' Contribution

Conceptualization: MUK

Methodology: MUK, HU, ZA, MJJ

Formal analysis: HU, SA, ZA, MJJ

Writing and Drafting: SA, JK

Review and Editing: SA, JK, MUK, HU, ZA, MJJ

All authors approved the final manuscript and take responsibility for the integrity of the work

Conflicts of Interest

All the authors declare no conflict of interest.

Source of Funding

The author received no financial support for the research, authorship and/or publication of this article.

REFERENCES

- [1] Parsons JL, Coen SE, Bekker S. Anterior cruciate ligament injury: towards a gendered environmental approach. *British Journal of Sports Medicine*. 2021 Sep; 55(17): 984-90. doi: 10.1136/bjsports-2020-103173.
- [2] Rothrauff BB, Jorge A, de Sa D, Kay J, Fu FH, Musahl V. Anatomic ACL reconstruction reduces risk of post-traumatic osteoarthritis: a systematic review with minimum 10-year follow-up. *Knee Surgery, Sports Traumatology, Arthroscopy*. 2020 Apr; 28:1072-84. doi: 10.1007/s00167-019-05665-2.
- [3] Li R, Liu Y, Fang Z, Zhang J. Introducing the lateral femoral condyle index as a risk factor for anterior cruciate ligament injury. *The American Journal of Sports Medicine*. 2020 Jun; 48(7):NP42-.doi:10.1177/0363546520920546.
- [4] Li Z, Li C, Li L, Wang P. Correlation between notch width index assessed via magnetic resonance imaging and risk of anterior cruciate ligament injury: an updated meta-analysis. *Surgical and Radiologic Anatomy*. 2020 Oct; 42:1209-17. doi:10.1007/s00276-020-02496-6.
- [5] Pfeiffer TR, Burnham JM, Hughes JD, Kanakamedala AC, Herbst E, Popchak A et al. An increased lateral femoral condyle ratio is a risk factor for anterior cruciate ligament injury. *Journal of Bone and Joint Surgery*. 2018 May; 100(10):857-64. doi:10.2106/JBJS.17.01011.
- [6] Shi WL, Gao YT, Zhang KY, Liu P, Yang YP, Ma Y et al. Femoral tunnel malposition, increased lateral tibial slope, and decreased notch width index are risk factors for non-traumatic anterior cruciate ligament reconstruction failure. *Arthroscopy: The Journal of Arthroscopic and Related Surgery*. 2024 Feb; 40(2): 424-34. doi: 10.1016/j.arthro.2023.06.049.
- [7] Abdurahmanovich HO. Diagnostics of injuries of the soft tissue structures of the knee joint and their complications. *European research*. 2020; (1(37)): 33-5.
- [8] Zhang C, Xie G, Fang Z, Zhang X, Huangfu X, Zhao J. Assessment of relationship between three dimensional femoral notch volume and anterior cruciate ligament injury in Chinese Han adults: a retrospective MRI study. *International Orthopaedics*. 2019 May; 43: 1231-7. doi: 10.1007/s00264-018-4068-7.
- [9] Siouras A, Moustakidis S, Giannakidis A, Chalatsis G, Liampas I, Vlychou M et al. Knee injury detection using deep learning on MRI studies: a systematic review. *Diagnostics*. 2022 Feb; 12(2):537. doi:10.3390/diagnostics12020537.
- [10] Meier MP, Hochrein Y, Saul D, Seitz MT, Roch PJ, Jäckle K et al. Physiological Femoral Condylar Morphology in Adult Knees-A MRI Study of 517 Patients. *Diagnostics*. 2023 Jan; 13(3):350. doi:10.3390/diagnostics1303035

- 0.
- [11] Chaurasia A, Tyagi A, Santoshi JA, Chaware P, Rathinam BA, Rathinam BA. Morphologic features of the distal femur and proximal tibia: a cross-sectional study. *Cureus*. 2021 Jan; 13(1). doi: 10.7759 /cureus.12907.
- [12] Hart A, Sivakumaran T, Burman M, Powell T, Martineau PA. A prospective evaluation of femoral tunnel placement for anatomic anterior cruciate ligament reconstruction using 3-dimensional magnetic resonance imaging. *The American Journal of Sports Medicine*. 2018 Jan; 46(1):192-9. doi:10.1177/0363546517730577.
- [13] Attia MH, Kholief MA, Zaghloul NM, Kružić I, Anđelinović Š, Bašić Ž *et al*. Efficiency of the adjusted binary classification (ABC) approach in osteometric sex estimation: A comparative study of different linear machine learning algorithms and training sample sizes. *Biology*. 2022 Jun; 11(6):917. doi:10.3390/biology11060917.
- [14] Refaat M, El Shazly E, Elsayed A. Role of MR imaging in evaluation of traumatic knee lesions. *Benha Medical Journal*. 2020 Oct; 37(special issue (Radiology)):77-86. doi: 10.21608/bmfj.2020.110137.
- [15] Chia L, De Oliveira Silva D, Whalan M, McKay MJ, Sullivan J, Fuller CW *et al*. Non-contact anterior cruciate ligament injury epidemiology in team-ball sports: a systematic review with meta-analysis by sex, age, sport, participation level, and exposure type. *Sports Medicine*. 2022 Oct; 52(10):2447-67. doi:10.1007/s40279-022-01697-w.
- [16] World Population review. Peshawar, Pakistan Population. [Cited: 27th Aug 2024]. Available at: <https://worldpopulationreview.com/cities/pakistan/peshawar>.
- [17] Cheng FB, Ji XF, Lai Y, Feng JC, Zheng WX, Sun YF *et al*. Three dimensional morphometry of the knee to design the total knee arthroplasty for Chinese population. *The Knee*. 2009 Oct; 16(5):341-7. doi:10.1016/j.knee.2008.12.019.
- [18] Thompson WW. Vital signs: hepatitis C treatment among insured adults—United States, 2019–2020. *Morbidity and Mortality Weekly Report*. 2022 Aug; 71. doi:10.15585/mmwr.mm7132e1.
- [19] Şenişik S, Özgürbüz C, Ergün M, Yüksel O, Taskiran E, İşlegen Ç *et al*. Posterior tibial slope as a risk factor for anterior cruciate ligament rupture in soccer players. *Journal of Sports Science and Medicine*. 2011 Dec; 10(4): 763-767.
- [20] Dalury DF, Ewald FC, Christie MJ, Scott RD. Total knee arthroplasty in a group of patients less than 45 years of age. *The Journal of Arthroplasty*. 1995 Oct; 10(5):598-602. doi: 10.1016/S0883-5403(05)80202-5.
- [21] Souryal TO and Freeman TR. Intercondylar notch size and anterior cruciate ligament injuries in athletes: a prospective study. *The American Journal of Sports Medicine*. 1993 Jul; 21(4):535-9. doi:10.1177/036354659302100410.
- [22] Wang HM, Shultz SJ, Ross SE, Henson RA, Perrin DH, Schmitz RJ. ACL size and notch width between ACLR and healthy individuals: a pilot study. *Sports Health*. 2020 Jan; 12(1): 61-5. doi: 10.1177/1941738119873631.
- [23] Park JS, Nam DC, Kim DH, Kim HK, Hwang SC. Measurement of knee morphometrics using MRI: a comparative study between ACL-injured and non-injured knees. *Knee Surgery and Related Research*. 2012 Sep; 24(3): 180. doi: 10.5792/ksrr.2012.24.3.180.
- [24] Gultekin MZ, Dinçel YM, Keskin Z, Arslan S, Yıldırım A. Morphometric risk factors effects on anterior cruciate ligament injury. *Joint Diseases and Related Surgery*. 2022 Dec; 34(1): 130. doi: 10.52312/jdrs.2023.910.
- [25] Liu HC. Review of gross anatomy of the Chinese knee. *Taiwan yi xue hui za zhi. Journal of the Formosan Medical Association*. 1984 Mar; 83(3): 317-25.
- [26] Irarrázaval S. Variations in anterior cruciate ligament anatomy. *Operative Techniques in Orthopaedics*. 2017 Mar; 27(1): 8-13. doi: 10.1053/j.oto.2017.01.003.
- [27] Mensch JS and Amstutz HC. Knee morphology as a guide to knee replacement. *Clinical Orthopaedics and Related Research*. 1975 Oct; 1(112):231-41. doi:10.1097/00003086-197510000-00029.