



## Original Article

## Diagnostic Accuracy of Magnetic Resonance Imaging in Detection of Perianal Fistula keeping Surgical Findings as Gold Standard

Haider Ali<sup>1</sup>, Uzma Azmat<sup>1</sup>, Manoj Kumar<sup>2</sup> and Khadijah Abid<sup>3\*</sup>

<sup>1</sup>Department of Imaging and Radiology, Memon Medical Institute Hospital, Karachi, Pakistan

<sup>2</sup>Department of Radiology, The Indus Hospital and Health Network, Karachi Pakistan

<sup>3</sup>Department of Public Health, Shaheed Zulfikar Ali Bhutto Institute of Science and Technology, Karachi, Pakistan

## ARTICLE INFO

**Key Words:**

Diagnostic Accuracy, Perianal Fistula, Surgical Findings, Magnetic Resonance Imaging

**How to Cite:**

Ali, H., Azmat, U., Kumar, M., & Abid, K. (2022). Diagnostic Accuracy of Magnetic Resonance Imaging in Detection of Perianal Fistula keeping Surgical Findings as Gold Standard: Magnetic Resonance Imaging in Detection of Perianal Fistula. *Pakistan Journal of Health Sciences*, 3(07). <https://doi.org/10.54393/pjhs.v3i07.314>

**\*Corresponding Author:**

Khadijah Abid  
 Department of Public Health, Shaheed Zulfikar Ali Bhutto Institute of Science and Technology, Karachi, Pakistan  
[khadijahabid@gmail.com](mailto:khadijahabid@gmail.com)

Received Date: 4<sup>th</sup> November, 2022

Acceptance Date: 13<sup>th</sup> December, 2022

Published Date: 31<sup>st</sup> December, 2022

## ABSTRACT

An abnormal connection between the rectum or canal and the anal skin is called as a perianal fistula (PAF). MRI is considered as a gold standard for the imaging of PAF because of its operator dependence, non-invasive nature, excellent soft tissue contrast, superior field of view and multiplanar capabilities. **Objective:** To assess the validity of magnetic resonance imaging in detecting perianal fistulas while using surgical findings as the gold standard. **Methods:** From 1 January 2021 to 30 January 2022, a cross-validation research was carried out in the radiology department at Memon Medical Institute Hospital in Karachi, Pakistan. The research comprised 153 individuals with PAF ranging in age from 18 to 70 years and of either gender. A 1.5 T MR scanner was used to obtain the MRI. All techniques used a phased-array coil for image capture in all circumstances. The imaging volume encompassed the distal rectum, anal canal, and subcutaneous tissues. Fat saturation pictures were taken in the oblique, axial, and coronal planes. A radiologist examined images, and pertinent patient data were noted on a pre-drafted proforma. Histopathological and post-surgical results were acquired and documented. **Results:** The validity of MRI for the diagnosis of PAF was 82.4% by taking surgical findings as gold standard. **Conclusion:** For the assessment of PAF and the detection of abscesses, MRI is a beneficial and reliable preoperative examination.

## INTRODUCTION

An abnormal link between the rectum or canal and anal skin is known as a perianal fistula (PAF) [1,2]. Anal fissure-related inflammation, chronic cryptoglandular sepsis, radiation damage, inflammatory bowel disease, or conditions including rectal or anal cancer, as well as trauma, are the causes of this condition [3]. PAF has an incidence of 8.6 per 100,000 people and primarily affects men (male to female ratio=2:1) [1]. Males have a PAF incidence of 12.3 per 100,000 people, whereas females have a PAF incidence of 5.6 per 100,000 people [4]. PAF is not only irritating and painful, but it can also serve as a breeding ground for infection. The most frequent complain

is discharge accounting for 65% of the cases [2]. PAF leads to acute formation of abscess where prompt surgical decompression is important, thus most uncomplicated fistulae can be managed by fistulotomy [2]. Anal fistula treatment includes the removal of the original opening, any related tracts, and any additional openings without impairing continence. This necessitates precise identification of internal opening of fistula and any secondary abscesses or extensions [5,6]. For surgical planning, it would be advantageous to have a diagnostic technique that can precisely pinpoint the internal entrance of a perianal fistula [5,7]. Traditional fistulography,

endosonography, computed tomography, 3D ultrasounds, MRI and trans perineal ultrasound, have all been utilized in the past to identify PAF [7]. Cannulating the exterior aperture and injecting a water-soluble contrast into the fistula are both components of traditional fistulograms. The relationship between the tract, the external or internal sphincter, and the levator ani muscle is invisible clear because the major tract and its extensions do not fill with contrast when blocked with debris or pus, and the sphincter muscle feature is not observable [8]. Transrectal ultrasound enhances the ability to see fistulae and the connection they have to the muscles of anal sphincter. However, it has limitations including operator dependence, no imaging coronal plane and a small field of view [9]. CT fistulography is restricted by the fact that the fibrosis areas, fistula tract, and sphincter muscles all have comparable attenuation values. Multidetector row CT fistulography, with its isotropic voxels, is anticipated to enhance the outcomes of modality [9, 10]. However, MRI is considered as a reference standard for the imaging of PAF because of its operator dependence, non-invasive nature, excellent soft tissue contrast, superior field of view and multiplanar capabilities [1, 2]. In addition, MRI can properly diagnose the fistula tract in relation to the sphincter complex and its related problems such as abscesses and secondary tract [3]. A recent study found that MRI is 100% sensitive and 88% specific for the identification of PAF, and concluded that MRI has great sensitivity but low specificity for the diagnosis of PAF [11]. The role of MRI is well established in Western nations, however local data is sparse in this area [5-7,11,12]. Therefore, the goal of current study is to assess the validity of MRI for the detection of PAF by considering surgical findings as gold standard. This investigation would aid in establishing the accuracy of MRI in preoperative evaluation of PAF in ano, allowing needless radiation and diagnostic delay due to incomplete tract healing by granulation tissue to be avoided, as is the case with traditional fistulography. It would also assist to reduce unneeded procedures and complications.

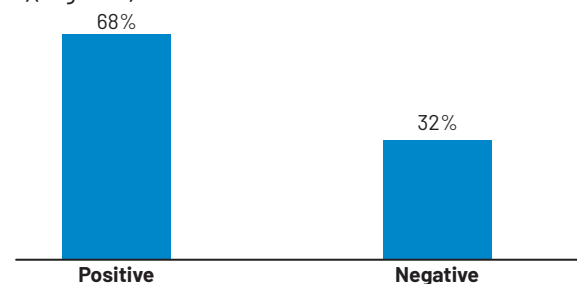
## METHODS

It was a cross-validation study conducted at the department of radiology of Memon Medical Institute Hospital (MMIH), Karachi from 1st Jan 2021 to 30th Jan 2022. Sample size of 153 patients was estimated using WHO sample size calculator by taking proportion of fistula in ano as 20% [13], bond on error as 6.4% and 95% confidence level. The research included all probable patients with PAF (had a perianal external skin opening or having watery, blood-tinged, or purulent discharge from the opening) aged 18 to 70 years of either gender. Patients who had surgery for perianal fistula, those with recurrent perianal sinus opening with history of perianal

fistulectomy, and patients with cardiac pacemakers indwelling metallic implants were not included in the study. Written informed permission was obtained from patients presenting with discharging perianal sinus on physical examination and referred to the department of radiology for MRI of pelvis for PAF after approval from the institutional review board. A 1.5 T MR scanner was used to obtain the MRI. All techniques used a phased-array coil for image capture in all circumstances. The imaging volume encompassed the distal rectum, anal canal, and subcutaneous tissues. Fat saturation pictures were taken in the axial, oblique, and coronal planes. A radiologist reviewed the images and noted important patient data on the pre-drafted proforma. Histopathological and post-surgical results were acquired and documented. SPSS version 22.0 was used to enter and evaluate the acquired data. For numerical data, mean and standard deviation were presented. For categorical data, frequency and percentage were presented. Using surgical results as the gold standard, the 2 by 2 table was utilized to compute validity of MRI for the detection of PAF.

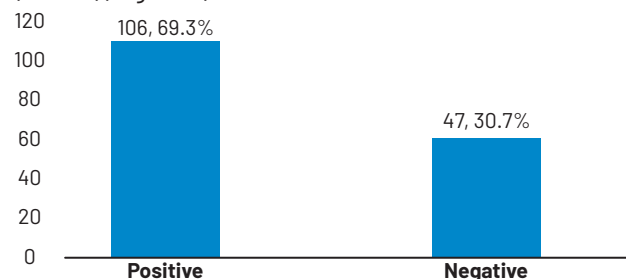
## RESULTS

The overall mean age was  $45.11 \pm 15.22$  years with range 20 to 69 years. There were 69 males (45.1%) and 84 females (54.9%) patients in the study. The overall duration since diagnosis on conventional MRI/ Surgery was  $3.46 \pm 1.18$  weeks ranging from 1 to 5 weeks. MRI findings showed PAF in 107 (68%) patients and no inflammation in 46 patients (32%) (Figure 1).



**Figure 1:** Frequency distribution of MRI findings for perianal fistula (n=153)

Post-surgery histopathology showed positive findings PAF in 106 (69.3%) patients and negative findings in 47 patients (30.7%) (Figure 2).



**Figure 2:** Frequency distribution of surgical findings for perianal

fistula(n=153)

PAF was identified on MRI and confirmed on surgical findings in 93 cases (true positives) and absence of PAF in 33 patients (true negatives). While, 13 patients shown no PAF on MRI but surgical findings detected it in 13 cases (false negatives). Furthermore, surgical findings denied the presence of PAF in 14 cases which was previously identified by MRI (false positives). Thus, preoperative evaluation of PAF on MRI could detect disease on post-surgery histopathology with Sn, Sp, and accuracy of 87.74% (95% CI=79.9% to 93.3%), 70.2% (95% CI=55.1% to 82.6%) and 82.4% (95% CI=75.4% to 88%), respectively. The PPV and NPV for MRI were estimated as 86.92% (95% CI=80.9% to 91.2%) and 71.4% (95% CI=75.37% to 88%)(Table 1).

MRI Findings	Surgical Findings			Statistic
	Positive (n=106)	Negative (n=47)	Total	
Positive (n=107)	93 (86.9%)	14 (13.1%)	107	Sn=87.7% Sp=70.2% PPV=86.9% NPV=71.7% Accuracy=82.4%
Negative (n=46)	13 (28.3%)	33 (71.7%)	46	
Total	106	47	153	

**Table 1:** Validity of MRI findings for the identification of PAF by taking surgical findings as gold standard

## DISCUSSION

Traditional fistulography, computed tomography, and ultrasound have all failed to diagnose disease accurately [10, 14]. The MRI role in the assessment of fistula-ano was originally established by Koelbel et al., in 1989, and followed by several researchers [2, 15]. We also tested the diagnostic accuracy of MRI for detecting perianal fistulas in the current investigation, considering surgical findings as the gold standard. In our study, the Sn of MRI for PAF diagnosis using surgical findings as gold standard was 87.7%, the Sp was 70.2%, and the diagnostic accuracy was 82.4%. In their study, Singh et al., discovered that MRI has a Sn of 96% and a Sp of 80% in correctly classifying and grading primary tract [2]. Ishfaq et al., found that MRI was 93% sensitive, 92% specific and 92% accurate in detecting PAF by taking surgical findings as gold standard [3]. Tantiphlachiva et al., conducted research on 25 patients which reported that Sn and Sp of MRI for PAF detection were 100% and 88% [9]. Siddiqui et al., concluded that MRI was better than digital rectal exam without or with surgical exploration for detection of fistulas, and that MRI was 97 percent sensitive and 100 percent specific [16]. Garg et al., discovered that MRI had excellent accuracy for detecting fistula-in-ano and provided useful information on previously unknown complicated factors, proving its significance as a critical pre-operative imaging technique for fistula-in-ano [17]. Villa et al., conducted the study to assess validity of MRI in fistula tracts and abscesses. They found MRI was 96% sensitive and 97% specific for the identification of abscesses, while MRI was 100% sensitive

and 86% specific for the detection of primary tracts [18]. Similar findings were observed by Rehman et al., and shown that MRI had a specificity of 100% and sensitivity of 90% in identifying type and extent of PAF [19]. MRI accurately detected the opening of an internal fistula and its link to sphincters. The addition of DW-MRI to STIR WI improves sensitivity and specificity for assessing fistula activity and extension, making it a valuable sequence with the greatest diagnostic output. Lee et al., used MRI as a comparative reference standard and reported transperitoneal ultrasound correlated with MRI results with PPV and Sn of 84.2% and 76.3% for detection of fistula and Sn of 56.3% and PPV of 90% for detection of abscess, respectively, whereas colonoscopy correlated with MRI results with Sn and PPV of 68% [20]. In the current investigation, we discovered that the PPV was 87% and the NPV was 72%. In contrast, Singh et al., reported a PPV value of 98% for MRI in their study [2]. Because of the small sample size in this research, more studies with a larger sample size and based in multi-hospitals are needed. In this way, the findings may be generalizable to wider populations.

## CONCLUSION

For the assessment of PAF and the detection of abscesses, MRI is a beneficial and reliable preoperative examination.

## Conflicts of Interest

The authors declare no conflict of interest.

## Source of Funding

The author(s) received no financial support for the research, authorship and/or publication of this article.

## REFERENCES

- [1] Gage KL, Deshmukh S, Macura KJ, Kamel IR, Zaheer A. MRI of perianal fistulas: bridging the radiological-surgical divide. *Abdom Imaging*. 2013 Oct; 38(5): 1033-42. doi: 10.1007/s00261-012-9965-4.
- [2] Singh K, Singh N, Thukral C, Singh KP, Bhalla V. Magnetic resonance imaging (MRI) evaluation of perianal fistulae with surgical correlation. *Journal of Clinical and Diagnostic Research*. 2014 Jun; 8(6): Rc01-4. doi: 10.7860/jcdr/2014/7328.4417.
- [3] Ishfaq S, Qamar MA, Zaman M. Diagnostic accuracy of magnetic resonance imaging in perianal fistula taking surgical findings as gold standard. 2016 Jul; 10(3): 939-41.
- [4] Ashraf Y, Iqbal I, Khatoon S. Magnetic resonance imaging; the best imaging technique in detection of perianal fistulas with diagnostic accuracy. *Professional Medical Journal*. 2017 Apr; 24(04): 560-4. doi: 10.29309/tpmj/2017.24.04.1512.
- [5] Song KH. New techniques for treating an anal fistula. *Journal of Korean Society of Coloproctology*. 2012

- Feb; 28(1): 7-12. doi: 10.3393/jksc.2012.28.1.7.
- [6] Elzawawi M, Abdullah M, Bakr M. Role of magnetic resonance imaging in the diagnosis of perianal fistulae. *Menoufia Medical Journal*. 2018 Apr; 31(2): 494-501. doi: 10.4103/mmj.mmj\_386\_16.
- [7] Halligan S and Stoker J. Imaging of fistula in ano. *Radiology*. 2006 Apr; 239(1): 18-33. 10.1148/radiol.239.1041043.
- [8] Vo D, Phan C, Nguyen L, Le H, Nguyen T, Pham H. The role of magnetic resonance imaging in the preoperative evaluation of anal fistulas. *Scientific Reports*. 2019 Nov; 9(1): 17947. doi: 10.1038/s41598-019-54441-2.
- [9] Tantiplachiva K, Sahakitrungruang C, Pattanaarun J, Rojanasakul A. Effects of preoperative endoanal ultrasound on functional outcome after anal fistula surgery. *BMJ Open Gastroenterology*. 2019 Apr; 6(1): e000279. doi: 10.1136/bmjgast-2019-000279.
- [10] Balci S, Onur MR, Karaosmanoğlu AD, Karçaaltıncaba M, Akata D, Konan A, et al. MRI evaluation of anal and perianal diseases. *Diagnostic and Interventional Radiology*. 2019 Jan; 25(1): 21-7. doi: 10.5152/dir.2018.17499.
- [11] Daabis N, El Shafey R, Zakaria Y, Elkhadrawy O. Magnetic resonance imaging evaluation of perianal fistula. *The Egyptian Journal of Radiology and Nuclear Medicine*. 2013 Dec; 44(4): 705-11. doi: 10.1016/j.ejrn.2013.09.003.
- [12] ELessawy M, Nakshabandi NE, Boukai A, ELZubaidi SA. Magnetic resonance imaging in assessment of anorectal fistulae and its role in management. 2010: European Congress of Radiology-RANZCR Annual Scientific Meeting 2010. doi: 10.1594/ranzcr2010/R-0004.
- [13] Almeida IS, Wickramasinghe D, Weerakkody P, Samarasekera DN. Treatment of fistula in-ano with fistula plug: experience of a tertiary care center in South Asia and comparison of results with the West. *BMC Research Notes*. 2018 Jul; 11(1): 513. doi: 10.1186/s13104-018-3641-x.
- [14] Sharma A, Yadav P, Sahu M, Verma A. Current imaging techniques for evaluation of fistula in ano: a review. *Egyptian Journal of Radiology and Nuclear Medicine*. 2020 Jul ;51(1): 130. doi: 10.1186/s43055-020-00252-9.
- [15] Koelbel G, Schmiedl U, Majer MC, Weber P, Jenss H, Kueper K, et al. Diagnosis of fistulae and sinus tracts in patients with Crohn disease: value of MR imaging. *AJR American Journal of Roentgenology*. 1989 May; 152(5): 999-1003. doi: 10.2214/ajr.152.5.999.
- [16] Siddiqui MR, Ashrafian H, Tozer P, Daulatzai N, Burling D, Hart A, et al. A diagnostic accuracy meta-analysis of endoanal ultrasound and MRI for perianal fistula assessment. *Diseases of the Colon and Rectum*. 2012 May; 55(5): 576-85. doi: 10.1097/DCR.0b013e318249d26c.
- [17] Garg P, Singh P, Kaur B. Magnetic Resonance Imaging (MRI): Operative Findings Correlation in 229 Fistula-in-Ano Patients. *World Journal of Surgery*. 2017 Jun; 41(6): 1618-24. doi: 10.1007/s00268-017-3886-x.
- [18] Villa C, Pompili G, Franceschelli G, Munari A, Radaelli G, Maconi G, et al. Role of magnetic resonance imaging in evaluation of the activity of perianal Crohn's disease. *Europe Journal of Radiology*. 2012 Apr; 81(4): 616-22. doi: 10.1016/j.ejrad.2011.01.046.
- [19] Rehman IU, Akhtar S, Rana AI, Latif U, Saleem H, Chaudhary MY. MRI in the pre operative evaluation of perianal fistula. *Journal of Postgraduate Medical Institute*. 2014 Jul; 28(3): 264-9.
- [20] Lee EH, Yang HR, Kim JY. Comparison of Trans perianal Ultrasound with Colonoscopy and Magnetic Resonance Imaging in Perianal Crohn Disease. *Journal of Pediatrics Gastroenterology and Nutrition*. 2018 Apr; 66(4): 614-9. doi: 10.1097/mpg.0000000000001752.