



Original Article

Primary Trans-anal Endorectal Pull Through for The Management of Hirschsprung Disease: Our Experience of 20 Cases

Naveed Haider^{1*}, Muhammad Sulman Butt², Komal Varda³, Ferheen Shahbaz⁴, Maryam Ajaz⁴, Afeefa Saeed⁴ and Javeria Saleem⁴

¹Department of Pediatric Surgery, D.G. Khan Medical College and DHQ Teaching Hospital D.G. Khan, Pakistan

²Health department, RHC Habib Abad PHFMC, Kasur, Pakistan

³Akram Medical Complex, Lahore, Pakistan

⁴Department of Public Health, University of The Punjab, Lahore, Pakistan

ARTICLE INFO

Key Words:

Hirschsprung's Disease, Aganglionic Colon, Anastomotic Stricture, Transient Fecal Incontinence

How to Cite:

Haider, N. H., Sulman Butt, M. ., Varda, K. ., Shahbaz, F. ., Ajaz, M. ., Saeed, A. ., & Saleem, J. . (2022). Primary Trans-anal Endorectal Pull Through for The Management of Hirschsprung Disease: Our Experience of 20 Cases: Primary Trans-anal Endorectal Pull Through for Hirschsprung Disease. *Pakistan Journal of Health Sciences*, 3(06). <https://doi.org/10.54393/pjhs.v3i06.332>

***Corresponding Author:**

Naveed Haider

Department of Pediatric Surgery, D.G. Khan Medical College and DHQ Teaching Hospital D.G. Khan
relucenstar1@gmail.com

Received Date: 7th November, 2022

Acceptance Date: 17th November, 2022

Published Date: 30th November, 2022

ABSTRACT

Hirschsprung's disease can be defined in terms of the aganglionic part of the colon and the definitive treatment is a one-stage trans-anal endorectal pull-through surgery. **Objectives:** To find out the efficacy and safety of this one-stage pull-through. Mostly the surgery is done in early childhood or the neonatal period, as the case is less frequently reported in older children and adolescents. **Methods:** A retrospective study was conducted including 16 males and 4 females. 20 cases including children of 6 months to 14 years, all were diagnosed with Hirschsprung's disease in the study duration of two years. The diagnostic criteria of these patients included; Clinical history of delayed passage of meconium, contrast enema, and rectal biopsy. Definitive variables were; Age, sex, and length of the aganglionic part of the colon. **Results:** All the patients included in the study had distended abdomens and persistent constipation. All of them have an aganglionic colon, a diagnosing feature of Hirschsprung's disease. All patients underwent the trans-anal endorectal one-stage pull-through. The average operative time recorded was 150 minutes. Post-operative complications were also recorded including anastomosis leakage (only in one case; for that a diversion colostomy was done), anastomotic stenosis or stricture (not reported in any case), enterocolitis and perineum irritation (In four cases), Transient fecal incontinence is a major complication (11 cases had transient fecal incontinence which resolved spontaneously with 1 to 2 weeks). No death had been recorded. **Conclusion:** For the treatment of Hirschsprung's disease, primary trans-anal endorectal pull-through is a safe and efficient technique.

INTRODUCTION

Hirschsprung disease is mostly diagnosed in neonatal life. At a later age in older children, abdominal distension and chronic constipation were reported [1]. The principle of this surgical technique is the resection of an aganglionic part of the rectum followed by a pull-through of the ganglionic bowel down the anus [2]. This technique is frequently practiced in neonates and infants. There are fewer research and literature reports about this technique. Mostly the patients had well-defined zones of the ganglionic and aganglionic colon [3]. Patients who were

undergone colostomies had their treatments by traditional multistage conventional pull-through [4]. Development of new surgical techniques and minimally invasive surgeries for complex diseases like Hirschsprung's disease developed, and the primary endorectal transanal pull-through is one of the latest techniques. Conventionally transanal mucosectomy was common [5]. Although this disease is very common in low or middle-income countries. But the complex and detailed reports are available on a small sample size to evaluate the effectiveness and

proficiencies in detail. The one-stage endorectal pull is definitely more supportive in pediatric age of patients with good and fast recovery times than the conventional endorectal pull-through surgeries [6]. Primary trans-anal endorectal pull-through is the most successful technique in pediatric surgery. Many studies support this surgical technique due to its feasibility less operative time and less blood loss without any abdominal incision [7]. Post-operative complications were significantly low also the list of benefits includes fast recovery, early discharge, and cost-effectiveness. Multiple studies support this technique because of less occurrence of intraperitoneal bleeding [8]. This technique was uncommon in pediatric surgery. but recent studies support this technique more in infants at early diagnosis than in older children [9]. The chronic accumulation of feces in the colon leads to inflammation and makes this primary pull technique less effective. Inflammation in the colon leads to ulcerations which can harm the mucosa and sub-mucosa and chances of fibrosis and enterocolitis increase. The congenital abnormalities are needed to be diagnosed and treated at a very early age otherwise lead to difficulties in treatment. The primary trans-anal endorectal pull in infants required less operative time, low occurrence of bleeding on average, and fast recovery. The surgery in older children displayed with very dilated colon, the mesentery vessels are large and there are more chances of bleeding and enterocoagulations [10]. More stitches and prolonged surgery distress surgeons and patients' health as well. That's why surgery in older children over 2 years of age required pre-operative bowel preparations with anema to empty the stool from the colon so the extra dilation of the colon could be reduced. On average the operative time in older children is twice of infants [11]. Primary endorectal pull-through is a more supportive technique to prevent post-operative complications including colo-anal anastomosis and anastomosis leakage. The severity of this complication is very high, and it's the most severe early operative complication in colostomies [12]. The most common technical problem leading to anastomosis leakage is inadequate bowl preparations and tension in anastomosis which can also be a cause of inadequate stricter placements in correspondence to the nominal diameters [13]. An abdominal CT scan is the most common technique in the diagnosis of anastomosis leakage in an early phase. If the patient gets this complication, reoperation is done [14].

METHODS

From august 2020 to august 2022, 20 cases of diagnosed Hirschsprung disease, including children of 6 months to 14 years. 16 males and 4 females were included. The data and

medical records were recorded retrospectively. The variables under consideration included demographic features; age, gender, clinical presentation, level of aganglionosis, pathology reports complications, and outcome variables. A questionnaire was used to collect the following information. Demographic variables include age, and sex at the time of diagnosis. Diagnostic investigations, preoperative information. Operative details of the surgical procedure include; the orientation of the patient, the point at which submucosal dissection was done, colon mobilization and degree of movement of the colon, the size of the remaining colon, colon length being excised, estimated blood loss, and operative time. Post-operative details include; the time of recovery regaining peristalsis, time to start the oral feed, and passage of the first stool. Post-operative complications were also recorded including anastomotic leakage, anastomotic stenosis or stricture, enterocolitis, and perineum irritation, Transient fecal incontinence was a major complication. Preoperative bowel preparation was done in all patients; rectal irrigation with normal saline solution 20cc / kg two times a day, and digital rectal stimulations. Preoperative antibiotic prophylaxis was induced by amoxicillin and clavulanic acid. After the induction of general anesthesia, patients were adjusted to the operative table. eversion and entrance of the anus were permitted by stay sutures with an anocutaneous junction. The surgeon preferred the jackknife position to directly assess mesenteric vessels to expose the anal canal and retracted with stay sutures. Stay sutures were inserted in the circumferential row above the dentate line approximately 0.5 to 1cm. The incision was done on the rectal mucosa with distal orientation to traction sutures, the mucosa is circumferentially lifted with the help of a diathermy needle and the submucosal plane is developed. Once this plane was built, the dissections get easy to continue towards blunt dissection and infiltrating vessels were cauterized of the submucosa. proximal extension of mucosal tube traction facilitates the dissection till the peritoneal reflection level is achieved (10 to 15cm on average over the dentate line). The upper end of this muscular cuff was controlled by four stay sutures are used and the full thickness of the sigmoid colon is exposed. The dissection was done on the outer wall of the rectal muscle and Pulled through a segment of the rectum and sigmoid colon as shown in figure 1A. above the level of peritoneal reflection, the dissection is extended. The incision was done circumferentially on the rectal muscle. An intraoperative frozen section is performed when a transitional zone is exposed as shown in figure 1B. A piece of colon was resected and the sample was sent to the pathology department for a frozen section. Histological examination and confirmation of the transitional zone of

the colon were marked and mobilization is done at that point by dividing rectosigmoid vessels and cauterizing them. In the case of neonates, ligatures were not needed. Inversion of the long seromuscular cuff was done, and shortened to at least 5cm before returning it to the normal position outside the anus. Resection was done to the part of an aganglionic segment. At the dentate line and proximally a dissection was carried out on the submucosa. This defines the boundary of the ganglionic colon and at that point, resection was done using absorbable sutures. Coloanal anastomosis is done as shown in figure 1C. Normally the innervated bowel was pulled and anastomosed at the point of the remaining mucosal region above the dentate line using 4-0 absorbable sutures. Patients were allowed to feed the very next day of the procedure. Anal dilation was done in a routine follow-up in all neonates and children once or twice for up to three weeks. Follow-up sessions were organized once a week followed by once a month than up to 3 months afterward.

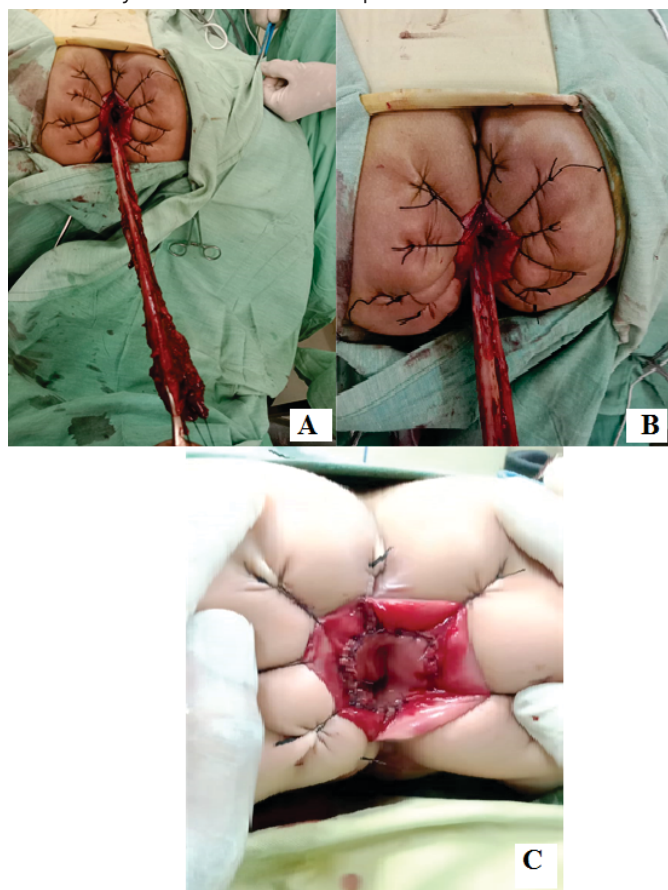


Figure 1: (A) Describes the Pulled through segment of rectum and sigmoid colon. (B) Shows Site of frozen section biopsy and (C) Explains anastomosis of ganglionic colon above dentate line

RESULTS

As a mean calculation of operative time was 150 minutes (90 to 180 minutes range). Statistically, significant time was

more in older patients than in neonates (120 90 v 80 40 minutes; p-value 0.05) in comparison to infants, the submucosal dissection was more difficult in older patients this refers to the thickness of their mesentery, long-standing dilated and also due to hypersigmoid colon. On average the length of resected bowel was 25cm to 12.5cm with a range of (15 to 45cm). Intraoperative time and blood loss were the main features, the average blood loss was 10 to 50 ml (on average 30 ml, 14% of total blood volume). The blood transfusion was not done in any case. The conversion rate was not found significant in all the cases. Average operative time and difficulties in operative procedure and post-operative complications all were recorded more in older patients than in neonates as described in table 1.

Indices	Ranges	Average Value/ Mean/ Ratio
The Average Age of Patients At Operation	6 months to 14 years	3 years
Sex Of Patients	16 boys (80 %) and 4 girls (20 %).	4:1
Average Length Of Resected Bowel	15 to 45cm	25cm
Blood Loss During Operation	10 to 50 ml	30 ml
Operative Time	90 to 180 minutes range	110 minutes
Hospital Stay	4 to 7 days	5 days

Table 1: Patients indices with Hirschsprung's Disease

Table 2 describes the Post-operative complications summarized in the table below, were also recorded including anastomosis leakage (only in one case; for that a diversion colostomy was done), anastomotic stenosis or stricture (not reported in any case), enterocolitis, and perineum irritation (In four cases), Transient fecal incontinence is a major complication (11 cases had transient fecal incontinence which resolved spontaneously with 1 to 2 weeks). No death had been recorded.

Postoperative Complications	No of Cases	Frequencies
Anastomosis Leakage	1 case	0.05%
Anastomotic Stenosis	No case reported	
Enterocolitis and Perineum Irritation	4 cases	0.2%
Transient Fecal Incontinence	11 cases	0.55%
Death	No case reported	

Table 2: Occurrence of post-operative complications

DISCUSSION

Hirschsprung's Disease is best treated via save and primary transanal endorectal pull-through. Sometimes the endorectal pull-through is followed by laparotomy [2]. Laparotomy should not be considered a failure for the primary surgical technique the target is to dissect the aganglionic part of the colon which should be done for the complete treatment of the disease not just to avoid the laparotomy the aganglionic part can be left undissected after surgery [15]. The complications which are more

common in older children than in infants, rare cases of infants who have sensitive skin and have more chances of perineum irritation [16]. On the other hand, Holschneider et al., found that if we discuss enterocolitis was more common in children at the infant age than in children above 2 years the reason is the immature of the underdeveloped enteric nervous system. Anal incontinence is a less frequent complication studied via the literature of pediatric surgery with a frequency of 1 to 10% in variant cases [16, 17]. Kim et al., literature also provided evidence about other complications, like soiling, the incidence of soiling was found to be 13% in many studies. Kim et al., study showed that soiling was 13% in neonates and 20% in children above two years of age [18]. We can conclude that soiling is more in older children than in neonates. This phenomenon finds its explanation more in the dilation of the colon and the size of the aganglionic area. The management is done via behavioral and cognitive therapies and the follow-up of patients. Constipation is considered among post-operative complications. With an occurrence rate of 10%. Not common among children with Hirschsprung's disease [19]. There are many studies found to provide a comparison of these surgical techniques. The traditional pull-through procedures and primary trans-anal endorectal pull-through surgery. The studies provide comparisons in feasibilities, safety, operative time, and post-operative complications [4]. Limitations are also under consideration for the one-stage technique when the aganglionic segment of the sigmoid colon is pulled through the endorectal. The lower one-third of the descending colon is pulled out of the anus because it is loosely attached to the peritoneum [5]. A histopathology frozen section is the evidence for the sigmoid colon. Pratap et al., studied that there were cases with laparotomy, firstly they start the procedure transanally then switch to laparotomy if the histologically provide frozen section is not reached from the below [20]. Rare cases of total colonic aganglionosis are also treated with the same procedure endorectal pull then conversion towards the laparotomy after completing the trans-anal mucosectomy. Marty et al., provided evidence for the best supportive and surgical procedures with respect to the surgical position of the patients, the most recommended position is the supine position than the prone position. The effect of controlling the mesenteric vessels is the main concern [21]. The significant stretching of the anal sphincter and an initial step for the primary transanal endorectal pull-through during mucosectomy. This procedure may lead an impact on postoperative continence status. This impact is more common in older children than in infants who have marked hypertrophy and dilation of the colon [22]. Wester et al., studied that patients undergoing conventional endorectal

pull-through surgeries have a low occurrence of postoperative constipation because of constant and low anastomosis [23]. But if we compare the conventional endorectal approach with the recent studies definitely the primary endorectal pull-through technique is the most efficient surgical technique in pediatric surgery. With less incidence of complications [24]. Early postoperative feeding, shorter hospital stay, less scaring, low bleeding during the surgery, and also cost-effective. The technique was easy to learn for practicing surgeons and considered the best treatment for the treatment of Hirschsprung's disease. Many studies support the evidence that primary transanal endorectal pull-through has been set the gold standard treatment for the treatment of Hirschsprung's disease [25].

CONCLUSIONS

In infants and children with Hirschsprung's disease, the surgical treatment of primary endorectal pull-through technique is the most efficient technique with less occurrence of morbidities and mortalities.

Conflicts of Interest

The authors declare no conflict of interest

Source of Funding

The author(s) received no financial support for the research, authorship and/or publication of this article

REFERENCES

- [1] De la Torre-Mondragon L and Ortega-Salgado JA. Transanal endorectal pull-through for Hirschsprung's disease. *Journal of Pediatric Surgery*. 1998 Aug; 33(8):1283-6. [doi: 10.1016/S0022-3468\(98\)90169-5](https://doi.org/10.1016/S0022-3468(98)90169-5)
- [2] Langer JC, Minkes RK, Mazziotti MV, Skinner MA, Winthrop AL. Transanal one-stage Soave procedure for infants with Hirschsprung's disease. *Journal of Pediatric Surgery*. 1999 Jan; 34(1):148-52. [doi:10.1016/S0022-3468\(99\)90246-4](https://doi.org/10.1016/S0022-3468(99)90246-4)
- [3] Albanese CT, Jennings RW, Smith B, Bratton B, Harrison MR. Perineal one-stage pull-through for Hirschsprung's disease. *Journal of Pediatric Surgery*. 1999 Mar; 34(3):377-80. [doi: 10.1016/S0022-3468\(99\)90480-3](https://doi.org/10.1016/S0022-3468(99)90480-3)
- [4] Liu DC, Rodriguez J, Hill CB, Loe Jr WA. Transanal mucosectomy in the treatment of Hirschsprung's disease. *Journal of Pediatric Surgery*. 2000 Feb; 35(2):235-8. [doi: 10.1016/S0022-3468\(00\)90016-2](https://doi.org/10.1016/S0022-3468(00)90016-2)
- [5] Langer JC, Seifert M, Minkes RK. One-stage Soave pull-through for Hirschsprung's disease: a comparison of the transanal and open approaches. *Journal of Pediatric Surgery*. 2000 Jun; 35(6):820-2. [doi: 10.1053/jpsu.2000.6849](https://doi.org/10.1053/jpsu.2000.6849)

- [6] De la Torre L and Ortega A. Transanal versus open endorectal pull-through for Hirschsprung's disease. *Journal of Pediatric Surgery*. 2000 Nov; 35(11):1630-2. doi: [10.1053/jpsu.2000.18338](https://doi.org/10.1053/jpsu.2000.18338)
- [7] Höllwarth M, Rivosecchi M, Schleef J, Deluggi S, Fasching G, Ceriati E, et al., The role of transanal endorectal pull-through in the treatment of Hirschsprung's disease—a multicenter experience. *Pediatric Surgery International*. 2002 Jul; 18(5):344-8. doi: [10.1007/s00383-002-0747-x](https://doi.org/10.1007/s00383-002-0747-x)
- [8] Teeraratkul S. Transanal one-stage endorectal pull-through for Hirschsprung's disease in infants and children. *Journal of Pediatric Surgery*. 2003 Feb; 38(2):184-7. doi: [10.1053/jpsu.2003.50039](https://doi.org/10.1053/jpsu.2003.50039)
- [9] Ergün O, Çelik A, Dökümcü Z, Balık E. Submucosal pressure-air insufflation facilitates endorectal mucosectomy in transanal endorectal pull-through procedure in patients with Hirschsprung's disease. *Journal of Pediatric Surgery*. 2003 Feb; 38(2):188-90. doi: [10.1053/jpsu.2003.50040](https://doi.org/10.1053/jpsu.2003.50040)
- [10] Saltzman DA, Telander MJ, Brennom WS, Telander RL. Transanal mucosectomy: A modification of the Soave procedure for Hirschsprung's disease. *Journal of Pediatric Surgery*. 1996 Sep; 31(9):1272-5. doi: [10.1016/S0022-3468\(96\)90249-3](https://doi.org/10.1016/S0022-3468(96)90249-3)
- [11] Georgeson KE, Fuenfer MM, Hardin WD. Primary laparoscopic pull-through for Hirschsprung's disease in infants and children. *Journal of Pediatric Surgery*. 1995 Jul; 30(7):1017-22. doi: [10.1016/0022-3468\(95\)90333-X](https://doi.org/10.1016/0022-3468(95)90333-X)
- [12] Elhalaby EA, Coran AG, Blane CE, Hirschl RB, Teitelbaum DH. Enterocolitis associated with Hirschsprung's disease: a clinical-radiological characterization based on 168 patients. *Journal of Pediatric Surgery*. 1995 Jan; 30(1):76-83. doi: [10.1016/0022-3468\(95\)90615-0](https://doi.org/10.1016/0022-3468(95)90615-0)
- [13] Gao Y, Li G, Zhang X, Xu Q, Guo Z, Zheng B, Li P, et al., Primary transanal rectosigmoidectomy for Hirschsprung's disease: Preliminary results in the initial 33 cases. *Journal of Pediatric Surgery*. 2001 Dec; 36(12):1816-9. doi: [10.1053/jpsu.2001.28847](https://doi.org/10.1053/jpsu.2001.28847)
- [14] Van Leeuwen K, Geiger JD, Barnett JL, Coran AG, Teitelbaum DH. Stooling and manometric findings after primary pull-throughs in Hirschsprung's disease: Perineal versus abdominal approaches. *Journal of Pediatric Surgery*. 2002 Sep; 37(9):1321-5. doi: [10.1053/jpsu.2002.34999](https://doi.org/10.1053/jpsu.2002.34999)
- [15] Elhalaby EA, Teitelbaum DH, Coran AG, Heidelberger, KP. Enterocolitis associated with Hirschsprung's disease: A clinical histopathological correlative study. *Journal of Pediatric Surgery* 1995 Jul; 30(7):1023-1027. doi: [10.1016/0022-3468\(95\)90334-8](https://doi.org/10.1016/0022-3468(95)90334-8)
- [16] Holschneider AM, Ure BM, Pfrommer W, Meier-Ruge W. Innervation patterns of the rectal pouch and fistula in anorectal malformations: a preliminary report. *Journal of Pediatric Surgery*. 1996 Mar; 31(3):357-62. doi: [10.1016/S0022-3468\(96\)90738-1](https://doi.org/10.1016/S0022-3468(96)90738-1)
- [17] De La Torre L and Langer JC. Transanal endorectal pull-through for Hirschsprung disease: technique, controversies, pearls, pitfalls, and an organized approach to the management of postoperative obstructive symptoms. In *Seminars in pediatric surgery* 2010 May; 19(2): 96-106. WB Saunders. doi: [10.1053/j.sempedsurg.2009.11.016](https://doi.org/10.1053/j.sempedsurg.2009.11.016)
- [18] Kim AC, Langer JC, Pastor AC, Zhang L, Sloots CE, Hamilton NA, et al. Endorectal pull-through for Hirschsprung's disease—a multicenter, long-term comparison of results: transanal vs transabdominal approach. *Journal of Pediatric Surgery*. 2010 Jun; 45(6):1213-20. doi: [10.1016/j.jpedsurg.2010.02.087](https://doi.org/10.1016/j.jpedsurg.2010.02.087)
- [19] Pratap A, Shakya VC, Biswas BK, Sinha A, Tiwari A, Agrawal CS, et al. Single-stage transanal endorectal pull-through for Hirschsprung's disease: perspective from a developing country. *Journal of Pediatric Surgery*. 2007 Mar; 42(3):532-5. doi: [10.1007/BF02722679](https://doi.org/10.1007/BF02722679)
- [20] Pratap A, Gupta DK, Shakya VC, Adhikary S, Tiwari A, Shrestha P, et al. Analysis of problems, complications, avoidance and management with transanal pull-through for Hirschsprung disease. *Journal of Pediatric Surgery*. 2007 Nov; 42(11):1869-76. doi: [10.1016/j.jpedsurg.2007.07.017](https://doi.org/10.1016/j.jpedsurg.2007.07.017)
- [21] Marty TL, Seo T, Matlak ME, Sullivan JJ, Black RE, Johnson DG. Gastrointestinal function after surgical correction of Hirschsprung's disease: long-term follow-up in 135 patients. *Journal of Pediatric Surgery*. 1995 May; 30(5):655-8. doi: [10.1016/0022-3468\(95\)90682-7](https://doi.org/10.1016/0022-3468(95)90682-7)
- [22] Marquez TT, Acton RD, Hess DJ, Duval S, Saltzman DA. Comprehensive review of procedures for total colonic aganglionosis. *Journal of Pediatric Surgery*. 2009 Jan; 44(1):257-65. doi: [10.1016/j.jpedsurg.2008.10.055](https://doi.org/10.1016/j.jpedsurg.2008.10.055)
- [23] Wester T and Rintala RJ. Early outcome of transanal endorectal pull-through with a short muscle cuff during the neonatal period. *Journal of Pediatric Surgery*. 2004 Feb; 39(2):157-60. doi: [10.1016/j.jpedsurg.2003.10.007](https://doi.org/10.1016/j.jpedsurg.2003.10.007)
- [24] Marty TL, Matlak ME, Hendrickson M, Black RE, Johnson DG. Unexpected death from enterocolitis

- after surgery for Hirschsprung's disease. *Pediatrics*.
[25] 1995 Jul; 96(1):118-21. [doi: 10.1542/peds.96.1.118](https://doi.org/10.1542/peds.96.1.118)
Little DC and Snyder CL. Early and late complications following operative repair of Hirschsprung's disease. In *Hirschsprung's disease and allied disorders 2008*: 375-85. Springer, Berlin, Heidelberg. [doi: 10.1007/978-3-540-33935-9_29](https://doi.org/10.1007/978-3-540-33935-9_29)