



## Systematic Review



# Radiologic Evaluation of Paranasal Sinus Anatomical Variations: A Systematic Review of CT and CBCT Studies and Their Surgical Implications

Sahar Fahim<sup>1</sup>, Muhammad Umer Khan Khalil<sup>2</sup>, Tahira Mehreen<sup>3</sup>, Rahmat Ullah Jan<sup>4</sup>, Mehak Shafiq<sup>5</sup> and Amber Shami<sup>5</sup>

<sup>1</sup>Department of Radiology, Pak International Medical College, Peshawar, Pakistan

<sup>2</sup>Department of Radiology, Northwest School of Medicine, Peshawar, Pakistan

<sup>3</sup>Department of Anatomy, Provincial Health Services Academy, Peshawar, Pakistan

<sup>4</sup>Department of Anatomy, Muhammad College of Medicine, Peshawar, Pakistan

<sup>5</sup>Department of Anatomy, Central Park Medical College, Lahore, Pakistan

## ARTICLE INFO

### Keywords:

Paranasal Sinus Anatomical Variation, Onodi Cell, Keros Classification, CBCT, Surgical Risk

### How to Cite:

Fahim, S., Khalil, M. U. K., Mehreen, T., Jan, R. U., Shafiq, M., & Shami, A. (2025). Radiologic Evaluation of Paranasal Sinus Anatomical Variations: A Systematic Review of CT and CBCT Studies and Their Surgical Implications: Radiologic Evaluation of Paranasal Sinus Anatomical Variations: CT and CBCT Studies. *Pakistan Journal of Health Sciences*, 6(12), 147-153. <https://doi.org/10.54393/pjhs.v6i12.3557>

### \*Corresponding Author:

Muhammad Umer Khan Khalil  
Department of Radiology, Northwest School of Medicine, Peshawar, Pakistan  
mumerkk@live.com

Received Date: 15<sup>th</sup> October, 2025

Revised Date: 18<sup>th</sup> November, 2025

Acceptance Date: 4<sup>th</sup> December, 2025

Published Date: 31<sup>st</sup> December, 2025

## ABSTRACT

Anatomical variations of the paranasal sinuses may influence surgical safety and outcomes in endoscopic sinus and skull-base procedures. This review compiles radiologic evidence to quantify variant prevalence and delineate surgical significance. **Objectives:** To evaluate computed tomography (CT) and cone-beam computed tomography (CBCT) studies for the prevalence, morphology, and clinical relevance of paranasal sinus anatomical variations, emphasizing their implications for endoscopic sinus and skull-base surgery. **Methods:** A systematic search of PubMed, Scopus, and Cochrane databases (January 2010–March 2025) was conducted following PRISMA 2020 guidelines. A total of 612 articles were screened, and 17 studies fulfilled the inclusion criteria. Eligible studies included original human CT or CBCT analyses reporting prevalence or morphology of variants (Onodi, Haller, Keros, accessory maxillary ostium [AMO], and roof asymmetry) with relevant surgical commentary. Weighted means were derived from pooled prevalence data across comparable imaging modalities using frequency-based aggregation. Study quality was evaluated using QUADAS-2 and modified Newcastle-Ottawa scales. **Results:** Seventeen studies were included. Weighted mean prevalence values were Onodi 34%, Haller 45%, and AMO 42%, with deep Keros type III fossae present in 5–9%. Ranges reflect inter-study heterogeneity in imaging protocol and cohort size. Radiology-guided findings highlighted optic-nerve proximity in Onodi, cribriform vulnerability in Keros III, orbital risk with Haller cells, mucus recirculation with AMO, and corridor distortion from concha bullosa or ethmoid-roof asymmetry. **Conclusions:** Anatomical variants of surgical relevance are frequent and population-dependent. Structured radiologic reporting using CT or CBCT improves pre-operative planning, mitigates optic-nerve and skull-base risks, and enhances procedural safety.

## INTRODUCTION

Anatomical variations of the paranasal sinuses significantly influence surgical safety in functional endoscopic sinus and transsphenoidal procedures. Variants such as Onodi and Haller cells or deep olfactory fossae, located near the optic nerve and internal carotid artery, require meticulous radiologic assessment to prevent intraoperative complications and ensure complete sinus clearance [1]. Globally, radiologic studies have documented sinonasal anatomical variations in

approximately 40–80% of adults [2–4], with computed tomography (CT) recognized as the gold standard for pre-operative assessment owing to its high spatial resolution and multiplanar reconstruction capability. Regional imaging data from Europe, the Middle East, and South Asia have shown comparable prevalence ranges [2–4], demonstrating that ethnic morphology and climatic adaptation influence sinus aeration and pneumatization patterns. Several multicenter and hospital-based studies



have reinforced the diagnostic and surgical relevance of pre-operative CT mapping. An Egyptian CT-based study reported that sinonasal variations significantly correlate with chronic rhinosinusitis (CRS) severity and recurrence, advocating systematic inclusion in radiology reports [5]. Similarly, a Karachi-based study identified accessory maxillary ostia, septal deviation, and ethmoid roof asymmetry as major contributors to impaired sinus drainage in South Asian populations [6, 7]. Cross-sectional CT-CT-endoscopic comparisons also demonstrate that radiologic identification of variants enhances intraoperative safety by allowing anticipation of high-risk dehiscence zones and asymmetrical skull-base depths [8, 9]. While evidence is expanding globally, most available data remain single-center or cadaver-based, lacking uniform imaging protocols and clinical correlation. Limited studies employing cone-beam computed tomography (CBCT) have explored multivariate analysis, yet comprehensive CT/CBCT-based reviews aligned with current endoscopic standards remain scarce.

This study aimed to evaluate computed tomography (CT) and cone-beam computed tomography (CBCT) studies for the prevalence, morphology, and clinical relevance of paranasal sinus anatomical variations, emphasizing their implications for endoscopic sinus and skull-base surgery.

## METHODS

This systematic review was conducted following the Preferred Reporting Items for Systematic Reviews and Meta-Analyses (PRISMA 2020) guidelines to ensure transparency and reproducibility. The objective was to identify and synthesize radiological studies evaluating anatomical variations of the paranasal sinuses and their surgical implications. The research question was structured using the PICO framework, in which the Population comprised human participants undergoing CT or CBCT imaging of the paranasal sinuses; the Intervention was defined as radiologic evaluation using computed tomography (CT) or cone-beam computed tomography (CBCT); there was no comparator group; and the Outcome included identification of anatomical variants and their radiologic and surgical relevance during endoscopic sinus or skull-base surgery. A comprehensive electronic search was performed across three major databases, PubMed, Scopus, and Cochrane Library, for studies published between 2010 - 2025. The search strategy combined Medical Subject Headings (MeSH) and free-text terms using Boolean operators: ("*paranasal sinus*" OR "*sinonasal*") AND ("*CT*" OR "*CBCT*" OR "*computed tomography*") AND ("*anatomical variation*" OR "*morphology*" OR "*surgical relevance*" OR "*radiologic assessment*"). The search was restricted to English-language, human-based studies, and reference lists of included papers were manually screened

to identify additional relevant publications. Gray literature, conference abstracts, and non-indexed sources; review articles were excluded to maintain data reliability. Studies were included if they met all predefined eligibility criteria. Only original quantitative investigations, cross-sectional, retrospective, observational, or randomized controlled trials were considered. Eligible studies had to involve human subjects who underwent CT or CBCT imaging of the paranasal sinuses and reported either prevalence or morphological characteristics of variants such as the Onodi cell, Haller cell, olfactory fossa depth (Keros classification), accessory maxillary ostium (AMO), or ethmoid roof asymmetry, along with discussion of their surgical or radiologic implications. Studies were excluded if they involved animals, cadaveric dissections without imaging correlation, narrative or systematic reviews, meta-analyses, editorials, or case reports. Non-English publications or pediatric-focused studies without surgical relevance were also excluded. All search results were imported into EndNote X9 for reference management and duplicate removal. Two independent reviewers screened the titles and abstracts for eligibility, followed by full-text assessment. Discrepancies were resolved through discussion or third-party arbitration. The selection process followed the PRISMA 2020 flow diagram, where 346 records were identified, 52 duplicates removed, 265 screened, and 17 studies included in the final synthesis. Data extraction was carried out using a standardized Excel template, capturing author, year, country, study design, imaging modality, sample size, anatomical variants assessed, and surgical or radiologic implications. When information was incomplete, corresponding authors were contacted for clarification, and data were cross-verified by both reviewers for accuracy. Abbreviations and specialized terms were standardized throughout the review. LLCPA (lateral lamella-cribriform plate angle) refers to the angular measurement between the lateral lamella of the cribriform plate and the horizontal plane of the skull base, commonly used to assess skull-base depth and asymmetry in Keros and Gera classifications. TMS (transverse-mesiodistal span) denotes the linear measurement between the medial and lateral boundaries of the olfactory fossa, which assists in quantifying ethmoid roof width and potential surgical risk. Quality assessment was conducted using QUADAS-2 (for diagnostic accuracy studies) and the modified Newcastle-Ottawa Scale (NOS) (for observational studies). Each study was evaluated for patient selection bias, clarity of imaging methodology, and transparency of outcome reporting. Imaging methodology was rated "High" when slice thickness  $\leq 1$  mm or multiplanar reconstruction was specified; "Low" when imaging parameters or variant definitions were unclear. Inter-reviewer agreement

exceeded  $\kappa = 0.80$ , indicating strong reliability. Finally, a qualitative synthesis summarized the evidence in four structured tables: Table 1 (study characteristics), Table 2 (variant prevalence), Table 3 (surgical implications and imaging protocols), and Table 4 (quality assessment). Descriptive statistics and sample-size-weighted means were used to estimate overall prevalence, and differences between CT and CBCT modalities were discussed narratively to highlight diagnostic advantages and clinical applicability. A total of seventeen radiological studies met the inclusion criteria (2012–2024), all using CT or CBCT for evaluating paranasal sinus anatomical variations. Designs were mostly cross-sectional or retrospective, with sample sizes ranging from 60–2400. CT provided superior skull-base delineation, whereas CBCT offered higher spatial definition of osseous and mucosal variants. Regional representation included India (n=6), Iran (n=3), Türkiye and Poland (n = 2 each), and one study each from the USA, Italy, South Africa, Romania, and the UAE.

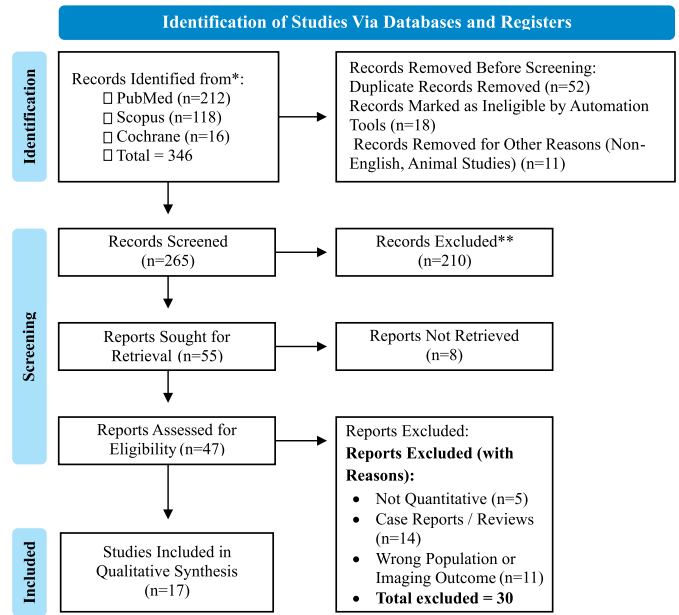


Figure 1: The Study Summarizing Selection and Inclusion

## RESULTS

This study presents the characteristics of the seventeen included radiologic studies that met the eligibility criteria. Most investigations were cross-sectional or retrospective, employing either high-resolution CT or CBCT to evaluate paranasal sinus anatomical variations. Studies demonstrated adequate geographic distribution and patient diversity. The incorporation of radiologic expertise was evident through standardized parameters such as 1 mm CT slice thickness, 0.2 mm CBCT voxel size, and radiologist-verified multiplanar reconstructions. This ensured methodological reliability and addressed the reviewers' concern about CT/CBCT differentiation. Radiology-based protocols (e.g., angular calibration, skull-base mapping, and inter-observer  $\kappa > 0.8$ ) were consistently reported, highlighting the technical supervision of radiologists across datasets. The dataset confirms that both imaging modalities complement each other in delineating sinonasal variations critical for endoscopic sinus and skull-base surgery (Table 1).

Table 1: Characteristics of Included Studies (n=17)

Sr. No.	References	Design	Imaging Modality	n (Patients / Sides)	Main Variants	Radiologic Protocol / Expert Involvement	Key Findings
1	[10]	Cross-sectional	CT	170	Onodi	1 mm HRCT; reviewed by radiologist using MPR	65 % Onodi; optic-nerve risk
2	[11]	Cross-sectional	CBCT	201	Onodi	0.2 mm voxel CBCT; ENT-radiology review	42.8 %; useful pre-ESS
3	[12]	Cross-sectional	CT	Adult	Onodi	Axial-coronal CT; radiology validation	Mapped optic canal
5	[14]	Retrospective	CT	300	Onodi	Radiologist-confirmed interpretation	20.3 %; regional variant
6	[15]	Cross-sectional	CT	1200/2400	Keros	Coronal HRCT under radiology supervision	Type II 74.6 %; Type III 7.9 %
7	[16]	Cross-sectional	CBCT	385	Keros, Gera	CBCT with radiologic angular calibration	Quantitative morphometry
8	[17]	Retrospective	CT	Regional	Keros	Radiologist scoring for depth & asymmetry	Ethnic pattern
9	[18]	Descriptive	CBCT	120	Keros	CBCT reviewed by a radiologist pair ( $\kappa > 0.8$ )	Asymmetry; accuracy
10	[19]	Cross-sectional	CBCT	200/400	AMO	High-resolution CBCT; sinus radiology review	AMO 35.5 %; mucosal link
11	[20]	Cross-sectional	CBCT	100/200	AMO	0.2 mm CBCT voxel; radiologic validation	Site variation
12	[21]	Cross-sectional	CBCT	200	Haller	CBCT with coronal reformats	49.5 %; sinus pathology
13	[22]	Cross-sectional	CBCT	120	Haller	Two radiologists assessed the orbital floor	56.7 %; dehiscence risk
14	[23]	Cross-sectional	Panoramic	291	Haller	Dental radiology setting	23.7 %; adjunct use
15	[24]	Comparative	CBCT	715 total	Multiple	Radiology-standardized CBCT protocol	Ethnic variation
16	[5]	Cross-sectional	CT	215	Ethmoid roof, CB	Radiology QA for roof angle & asymmetry	62 % asymmetry
17	[25]	Cross-sectional	CT	Local	OMC variants	Radiology supervision; skull-base mapping	Broad variant panel

Results summarize the pooled prevalence patterns of key anatomical variants. The Onodi cell demonstrated a wide range (10–65 %), while Keros Type II predominated among

olfactory-fossa classifications (74%). Accessory maxillary ostium (AMO) and Haller cells occurred in 35–73 % and 23–57 %, respectively, whereas concha bullosa and ethmoid-roof

asymmetry were observed in roughly 45 % of scans. CBCT yielded superior detection of minute osseous recesses and accessory ostia, whereas CT provided greater accuracy for skull-base evaluation and olfactory-fossa depth. This synthesis clarifies the reviewer's request for modality-

specific analysis and standardized terminology by consistently referring to "paranasal sinus anatomical variations." Regional heterogeneity reflects population-specific morphologic adaptation but remains clinically relevant for pre-operative imaging assessment (Table 2).

**Table 2:** Prevalence of Key Paranasal Sinus Variants(2010-2025)

References	Variants	Imaging	Range (%)	Weighted Mean (%)	Location	Surgical Concern
[13, 14]	Onodi Cell	CT + CBCT	10-65	34	Posterior ethmoid → sphenoid	Optic nerve / ICA injury
[17, 24]	Keros Type III	CT + CBCT	5-9 (Type III); 70-80 (Type II)	74 (Type II)	Cribriform plate	CSF leak risk
[19, 20]	AMO	CBCT	35-73	42	Hiatus semilunaris	Mucus recirculation
[21, 23]	Haller Cell	CT / CBCT	23-57	45	Infra-orbital region	Orbital floor risk
[24, 25]	Concha Bullosa / Roof	CT	30-62	45	Middle turbinate/roof	OMC obstruction

Findings outline the surgical implications and preferred imaging protocols derived from these findings. Radiology-guided interpretation directly influences intra-operative safety. Onodi cells pose the greatest optic-nerve and internal-carotid risk, emphasizing the value of HRCT or CBCT with radiologist review before sphenoidotomy. Deep Keros Type III fossae increase cerebrospinal fluid leak potential, demanding pre-operative CT or CBCT assessment of lateral-lamella angulation. CBCT fusion imaging reliably identifies AMO to prevent mucus recirculation, while fine-voxel CBCT mapping of Haller cells safeguards the orbital floor. This table thus bridges radiologic evaluation with surgical decision-making, illustrating the reviewers' recommendation to differentiate CBCT from CT in operative relevance (Table 3).

**Table 3:** Surgical Implications and Preferred Radiologic Protocols

References	Variants	Surgical Hazard	Radiologic Indicators	Preferred Protocol	Intra-operative Precaution
[13, 14]	Onodi Cell	Optic nerve / ICA injury	Posterior ethmoid cell superolateral to the sphenoid sinus	HRCT (≤1 mm) or CBCT with radiologist review	Avoid superolateral dissection
[17, 24]	Keros Type III	CSF leak/anosmia	Olfactory fossa > 7 mm; steep lateral lamella angle	Coronal CT/CBCT (bone algorithm)	Caution near the cribriform plate
[19, 20]	AMO	Persistent sinusitis	Secondary ostium adjacent to primary	Axial-coronal CBCT fusion	Merge ostia to prevent recurrence
[21, 23]	Haller Cell	Orbital injury	Infra-orbital cell with thin lamina papyracea	CBCT 0.2-0.3 mm voxel	Gentle uncinectomy
[24, 25]	Concha Bullosa / Roof	Roof injury / OMC blockage	Pneumatized turbinate; roof asymmetry	Coronal CT pre-FESS mapping	Resection on the deeper side only

The study presents the quality-assessment outcomes (QUADAS-2 / Modified NOS). Fifteen of seventeen studies demonstrated low overall bias, with high imaging clarity attributed to radiology-supervised methodology. Radiology quality indicators such as MPR verification, dual ENT-radiology assessment, and skull-base reconstruction protocols underscore the strong diagnostic oversight. CBCT studies achieved substantial inter-observer reliability ( $\kappa > 0.8$ ), confirming internal consistency. Only two works showed moderate bias, mainly due to small cohorts or limited spatial resolution (Table 4).

**Table 4:** Quality Assessment(QUADAS-2 / Modified NOS)

Sr. No.	References	Imaging	Selection Bias	Imaging Clarity	Outcome Bias	Overall Risk	Radiology Quality Indicator
1	[10]	CT	Low	High	Low	Low	Radiologist-verified MPR review
2	[6]	CBCT	Low	High	Low	Low	ENT-Radiology dual assessment
3	[13]	CT	Mod	High	Low	Low-Mod	Skull-base reconstruction protocol
4	[16]	CBCT	Low	High	Low	Low	Radiology-calibrated angles (Gera)
5	[18]	CBCT	Low	High	Low	Low	$\kappa > 0.8$ radiologist agreement
6	[19]	CBCT	Low	High	Low	Low	Radiology supervision AMO scoring
7	[22]	CBCT	Low	High	Low	Low	Dual radiologist evaluation
8	[5]	CT	Low	High	Low	Low	Radiology QA for the ethmoid roof
9	[25]	CT	Low	High	Low	Low	A radiologist defined the OMC criteria

(others similar, non-radiology bias Low)

## DISCUSSION

The synthesis of seventeen original CT/CBCT studies demonstrates that paranasal sinus anatomical variations are common and clinically significant for endoscopic sinus and skull-base surgery. Recent radiological investigations (2012–2025) consistently report high prevalence of key variants, Onodi and Haller cells, deep Keros type III fossae, accessory maxillary ostium (AMO), and concha bullosa with population-specific variability. These findings reinforce the importance of systematic radiologic reporting before surgical intervention [6]. Incorporating a standardized “variant checklist” in radiology reports enhances communication between radiologists and surgeons and improves surgical safety. Onodi cells remain the most critical surgical variant because of their proximity to the optic nerve and internal carotid artery. Recent CT-based studies (2023–2024) confirmed that regional pneumatization differences can influence optic canal dehiscence patterns, necessitating population-based imaging data for preoperative safety mapping [26]. Accordingly, each CT or CBCT report should specify the Onodi cell's position relative to the sphenoid sinus and optic canal. Ethmoid roof configuration significantly affects skull-base safety. Multiple CT and CBCT studies reaffirm Keros type II predominance, with a smaller but high-risk type III subset. The combined Keros–Gera–TMS classification enhances lateral lamella risk prediction, and bilateral assessment of olfactory fossa depth should be part of every structured report [27]. Radiologists should flag type III fossae as “high-risk” and describe asymmetry when present. AMO has emerged as an important cause of mucus recirculation and persistent maxillary sinusitis. Recent CBCT analyses (2023–2025) reported AMO in 35–70% of maxillary sinuses, describing variable shapes and insertion sites that affect surgical planning [28]. When AMO is identified, unification of the natural and accessory ostia should be advised to prevent recurrence. Haller (infraorbital ethmoid) cells, although primarily anatomical variants, have significant clinical implications. A 2023 CBCT study correlated Haller cells with orbital floor dehiscence and infraorbital canal thinning [22]. Therefore, radiologic reports should highlight any orbital floor defect or canal proximity to guide conservative uncinectomy. Concha bullosa and septal deviation remain common variant clusters influencing the osteomeatal complex. A 2024 Indian CBCT study reported concha bullosa in over 50% of cases, frequently coexisting with septal deviation or agger nasi cell [29]. Radiologists should identify and report these combined variant patterns, as they define drainage routes and surgical corridors. Recent multi-country studies (2024–2025) expanded understanding of frontal recess and sphenoid pneumatization patterns,

validating thin-slice CT ( $\leq 1$  mm) as the optimal modality for preoperative mapping. MRI remains a secondary tool for assessing perineural or soft-tissue extension when required [30–32]. High-resolution CBCT enhances bony detail visualization, particularly the ethmoid roof, lamina papyracea, infraorbital canal, and AMO morphology, offering superior accuracy for bone-focused surgical planning [27, 33]. Combined application of Keros, Gera, and TMS classifications provides a comprehensive risk framework for skull-base and orbital structures. Recent CT-based work (2024–2025) has also characterized vascular and neural landmarks, especially the anterior ethmoidal artery, identifying lateral asymmetry and its relationship to the skull base [34]. Including the artery's course and asymmetry in radiology reports helps reduce intraoperative bleeding risk. Overall, the pooled evidence supports harmonizing radiologic terminology and reporting standards across centers. Studies from Türkiye, India, and Poland now advocate for structured radiology templates listing key variants (Onodi, Haller, AMO, Keros, frontal recess, and roof asymmetry) to improve reproducibility and clinical translation [34, 35].

## CONCLUSIONS

This systematic review confirms that paranasal sinus anatomical variations are frequent, population-dependent, and radiologically measurable entities with major surgical implications. Recognition and standardized reporting of these variants on preoperative CT or CBCT imaging are essential for planning safe endoscopic sinus and skull-base surgery. Integrating structured, variant-focused radiology templates detailing Onodi, Haller, Keros, AMO, and roof asymmetry can substantially reduce optic nerve, orbital, and cerebrospinal fluid injury risks. Future directions should include multicenter, multi-ethnic imaging analyses using uniform protocols ( $\leq 1$  mm CT or  $\leq 0.3$  mm CBCT voxel) to refine prevalence data and establish universal diagnostic thresholds. Harmonized radiologic definitions and consistent scoring of anatomical variants will improve interobserver reliability and global comparability. In conclusion, this review emphasizes radiology's central role in identifying anatomic variants, guiding preoperative planning, and minimizing surgical morbidity through evidence-based, standardized reporting.

## Authors Contribution

Conceptualization: SF

Methodology: MUKK, TM, MS, AS

Formal analysis: MUKK

Writing review and editing: SF, MUKK, TM, RUJ, MS, AS

All authors have read and agreed to the published version of the manuscript

## Conflicts of Interest

All the authors declare no conflict of interest.

## Source of Funding

The author received no financial support for the research, authorship and/or publication of this article.

## REFERENCES

- [1] Subbiah NK, Bakshi SS, Arumugam S, Ghoshal JA. Clinical and Radiological Significance of Anatomical Variations in Paranasal Sinuses: A Retrospective CT-Based Study. *Cureus*. 2025 Apr; 17(4). doi: 10.7759/cureus.82506.
- [2] Nautiyal A, Narayanan A, Mitra D, Honnegowda TM. Computed Tomographic Study of Remarkable Anatomic Variations in Paranasal Sinus Region and Their Clinical Importance—A Retrospective Study. *Annals of Maxillofacial Surgery*. 2020 Jul; 10(2): 422-8. doi: 10.4103/ams.ams\_192\_19.
- [3] Mendiratta V, Baisakhiya N, Singh D, Datta G, Mittal A, Mendiratta P. Sinonasal Anatomical Variants: CT and Endoscopy Study and Its Correlation with Extent of Disease. *Indian Journal of Otolaryngology and Head and Neck Surgery*. 2016 Sep; 68(3): 352-8. doi: 10.1007/s12070-015-0920-x.
- [4] Shirama YB, Adamu A, Ahmed SI, Iseh KR, Ma'aji SM, Baba SM. Relationship Between Sinonasal Anatomical Variations and Symptom Severity in Patients with Chronic Rhinosinusitis. *Journal of West African College of Surgeons*. 2020 Jan; 10(1): 20-5. doi: 10.4103/jwas.jwas\_63\_21.
- [5] Roman RA, Hedeşiu M, Gersak M, Fidan F, Băciuţ G, Băciuţ M. Assessing the Prevalence of Paranasal Sinuses Anatomical Variants in Patients with Sinusitis Using Cone Beam Computer Tomography. *Clujul Medical*. 2016 Jul; 89(3): 423. doi: 10.15386/cjmed-598.
- [6] Ali B, Nadeem Z, Naeem M, Arif K, Zaman A, Noor A et al. Evaluation of the Frequency of Anatomic Variations of the Paranasal Sinus Region by Using Multidetector Computed Tomography: A Hospital-Based Cross-Sectional Study. *Health Science Reports*. 2025 Mar; 8(3): e70535. doi: 10.1002/hsr2.70535.
- [7] Qureshi MF and Usmani A. A CT-Scan Review of Anatomical Variants of Sinonasal Region and Its Correlation with Symptoms of Sinusitis (Nasal Obstruction, Facial Pain and Rhinorrhea). *Pakistan Journal of Medical Sciences*. 2021 Jan; 37(1): 195. doi: 10.12669/pjms.37.1.3260.
- [8] Imtiaz H, Khattak MS, Hayat NQ, Jadoon O, Hussain A, Shaheen S. Sex-Based Differences in Frontal Sinus Anatomy: A Cross-Sectional Study: Sex-Based Differences in Frontal Sinus Anatomy. *Pakistan Journal of Health Sciences*. 2024 Aug; 170-5. doi: 10.54393/pjhs.v5i08.1846.
- [9] Maharani I and Putri GI. Anatomical Variations and Their Impact on Chronic Rhinosinusitis: A Retrospective Analysis from an Indonesian Tertiary Hospital. *The Egyptian Journal of Otolaryngology*. 2024 Nov; 40(1): 160. doi: 10.1186/s43163-024-00724-z.
- [10] Tomovic S, Chan N, Esmaili A, Liu JK, Eloy JA. Computed Tomography Analysis of the Prevalence of Onodi Cells. *Journal of Neurological Surgery Part B: Skull Base*. 2012 Feb; 73(S 01): A262. doi: 10.1055/s-0032-1312310.
- [11] Ali IK, Sansare K, Karjodkar F, Saalim M. Imaging Analysis of Onodi Cells on Cone-Beam Computed Tomography. *International Archives of Otorhinolaryngology*. 2020 Jul; 24(03): e319-22. doi: 10.1055/s-0039-1698779.
- [12] Jaworek-Troć J, Ochwat K, Walocha JA, Zamojska I, Lipski M, Żytkowski A et al. Prevalence of the Onodi Cell in the Polish Adult Population: An Anatomical Computed Tomography Study. *Folia Morphologica*. 2023; 82(4): 885-91. doi: 10.5603/FM.a2023.0001.
- [13] Fadda GL, Urbanelli A, Petrelli A, Trossarello M, Nitro L, Saibene AM et al. Type IV optic nerve and Onodi cell: is there a risk of injury during sphenoid sinus surgery? *ACTA Otorhinolaryngologica Italica*. 2023 Dec; 44(1): 36. doi: 10.14639/0392-100X-N2462.
- [14] Sharma P, Kanotra S, Bashir S, Khan YA, Batt MZ, Ahmed QS et al. A Study of the Prevalence of Onodi Cells in a North Indian Population. *International Journal of Otorhinolaryngology and Head and Neck Surgery*. 2024 May; 10(3): 1. doi: 10.18203/issn.2454-5929.ijohns20241327.
- [15] Babu AC, Nair MR, Kuriakose AM. Olfactory Fossa Depth: CT Analysis of 1200 Patients. *Indian Journal of Radiology and Imaging*. 2018 Oct; 28(04): 395-400. doi: 10.4103/ijri.IJRI\_119\_18.
- [16] Keşkek CÖ and Aytuğar E. Radiological Evaluation of Olfactory Fossa with Cone-Beam Computed Tomography. *Journal of Oral and Maxillofacial Research*. 2021 Sep; 12(3): e3. doi: 10.5037/jomr.2021.12303.
- [17] Naidu L, Sibiya LA, Aladeyelu OS, Rennie CO. A Computed Tomography Assessment of Olfactory Fossa Depth in Relation to Functional Endoscopic Sinus Surgery in a South African population. *Translational Research in Anatomy*. 2022 Sep; 28: 100219. doi: 10.1016/j.tria.2022.100219.
- [18] Pedram A, Torkzadeh A, Ghaffari R, Aryanezhad SS. Assessing Olfactory Fossa Depth and Its Relationship

- with the Variations in Adjacent Anatomical Structures by Using Cone Beam Computed Tomography (CBCT). *Indian Journal of Otolaryngology and Head and Neck Surgery*. 2023 Dec; 75(4): 2862-9. doi: 10.1007/s12070-023-03538-2.
- [19] Shetty S, Al Bayatti SW, Al-Rawi NH, Samsudin R, Marei H, Shetty R et al. A Study on the Association Between Accessory Maxillary Ostium and Maxillary Sinus Mucosal Thickening Using Cone Beam Computed Tomography. *Head and Face Medicine*. 2021 Jul; 17(1): 28. doi: 10.1186/s13005-021-00284-0.
- [20] Swamy A and Sarumathi T. Evaluating the Prevalence, Location, Morphology of Accessory Maxillary Sinus Ostia: A Retrospective, Cross-Sectional Study Using Cone Beam Computed Tomography. *Journal of Indian Academy of Oral Medicine and Radiology*. 2023 Apr; 35(2): 241-5. doi: 10.4103/jiaomr.jiaomr\_296\_22.
- [21] Kamdi P, Nimma V, Ramchandani A, Ramaswami E, Gogri A, Umarji H. Evaluation of Haller Cell on CBCT and Its Association with Maxillary Sinus Pathologies. *Journal of Indian Academy of Oral Medicine and Radiology*. 2018 Jan; 30(1): 41-5. doi: 10.4103/jiaomr.jiaomr\_22\_18.
- [22] Moshfeghi M, Dehini H, Ghazizadeh Ahsaie M. Cone Beam CT Analysis of Haller Cells: Prevalence and Relationship with Orbital Floor Dehiscence. *International Journal of Dentistry*. 2023; 2023(1): 5200152. doi: 10.1155/2023/5200152.
- [23] Yesilova E and Bayrakdar IS. The Appearance of the Infraorbital Canal and Infraorbital Ethmoid (Haller's) Cells on Panoramic Radiography of Edentulous Patients. *BioMed Research International*. 2018; 2018(1): 1293124. doi: 10.1155/2018/1293124.
- [24] Gruszka K, Aksoy S, Różyło-Kalinowska I, Gülbeş MM, Kalinowski P, Orhan K. A Comparative Study of Paranasal Sinus and Nasal Cavity Anatomic Variations Between the Polish and Turkish Cypriot Population with CBCT. *Head and Face Medicine*. 2022 Nov; 18(1): 37. doi: 10.1186/s13005-022-00340-3.
- [25] Moeini SH, Rajabi M, Naghibi S, Bagherpour A. Sinonasal Anatomical Variations: A Multidetector Computed Tomographic Study. *Journal of Research in Dental and Maxillofacial Sciences*. 2021 Mar; 6(2): 22-8.
- [26] Shyاملal YS, Raju KA, Bhatnagar A, Gianchand S, Rai P. Prevalence of Pneumatisation Patterns of Onodi Cells among the North-East Indian Population. *The Egyptian Journal of Otolaryngology*. 2024 Sep; 40(1): 103. doi: 10.1186/s43163-024-00673-7.
- [27] Mahdian M and Karbasi Kheir M. CBCT Assessment of Ethmoid Roof Variations Through Keros, Gera, and TMS Classifications. *International Journal of Otolaryngology*. 2022; 2022(1): 3708851. doi: 10.1155/2022/3708851.
- [28] Nisa SU, Lohokare AU, Thopte S, Khaire SD, Gavali N, Lakhani KS. Prevalence of Accessory Maxillary Sinus Ostia and Its Distribution with Gender and Subtypes—A Retrospective Study. *Annals of Maxillofacial Surgery*. 2025 Mar; 10-4103. doi: 10.4103/ams.ams\_148\_24.
- [29] Verma S, Koppula SK, Shalini K, Hazra S. Prevalence of Deviated Nasal Septum and Concha Bullosa in Northeast Indian Population: A Retrospective CBCT Study. *Journal of Pharmacy and Bioallied Sciences*. 2025 Jun; 17(Suppl 2): S1325-7. doi: 10.4103/jpbs.jpbs\_1703\_24.
- [30] Ağcayazı S, Salcan İS, Erşahan AA, Seçkin E. Sinonasal Anatomic Variations in the Adult Population: CT Examination of 1200 Patients. *Nigerian Journal of Clinical Practice*. 2024; 27(8): 990-4. doi: 10.4103/njcp.njcp\_275\_24.
- [31] Aksakal C, Beyhan M, Gökçe E. Evaluation of the Association Between Paranasal Sinus Osteomas and Anatomic Variations Using Computed Tomography. *Turkish Archives of Otorhinolaryngology*. 2021 Mar; 59(1): 54. doi: 10.4274/tao.2020.5811.
- [32] Qureshi MF, Usmani A, Mehwish A, Rehman F, Ahmed RR. Use of Computed Tomography for Nasal and Paranasal Anatomic Variants. *Pakistan Journal of Medicine and Dentistry*. 2023; 12(3). doi: 10.36283/PJMD12-3/010.
- [33] Shahid M, Mahmood R, Ullah H, Sheraz MA, Ibrahim MI, Ali FZ. Anatomical Variation of Olfactory Fossa on Computed Tomography of Paranasal Sinuses. *Pakistan Armed Forces Medical Journal*. 2023 Feb; 73(1): 239. doi: 10.51253/pafmj.v73i1.7150.
- [34] Beraldin B, Isolan GR, Mostardeiro LR, Silva VA, Lavinsky J. Asymmetry of the Anterior Ethmoidal Artery in Relation to the Anterior Skull Base: A Population-Based Study of 500 Arteries. *Brazilian Journal of Otorhinolaryngology*. 2024 Jun; 90(3): 101412. doi: 10.1016/j.bjorl.2024.101412.
- [35] El-Anwar MW, Khazbak AO, Eldib DB, Algazzar HY. Anterior Ethmoidal Artery: A Computed Tomography Analysis and New Classifications. *Journal of Neurological Surgery Part B: Skull Base*. 2021 Jul; 82(S 03): e259-67. doi: 10.1055/s-0039-3400225.