



Original Article

Efficacy of Retromandibular Approach in The Management of Mandibular Subcondyle Fractures

Ajeet Kumar¹, Fida Hussain², Ali Raza^{3*}, Syed Wahib Asif Zaidi⁴, Tahera Ayub⁵ and Muhammad Shoaib⁶¹Department of Oral and Maxillofacial Surgery, Sir Syed College of Medical Sciences, Karachi, Pakistan²Department of Oral and Maxillofacial Surgery, Bhattai Dental and Medical College, Mirpurkhas³Department of Health, Government of Sindh, Pakistan⁴Department of Oral and Maxillofacial Surgery, Consultant's Medical and Dental Clinic, Karachi, Pakistan⁵Department of Oral and Maxillofacial Surgery, Liaquat College of Medicine and Dentistry, Karachi, Pakistan⁶Department of Oral Surgery, Hamdard University Dental Hospital, Karachi, Pakistan

ARTICLE INFO

Key Words:

Retromandibular Approach, Mandibular Subcondyle Fracture, Efficacy

How to Cite:

Kumar, A. ., Hussain, F. ., Raza, A. ., Wahib Asif Zaidi, S. ., Ayub, T. ., & Shoaib, M. . (2023). Efficacy of Retromandibular Approach in The Management of Mandibular Subcondyle Fractures: Retromandibular Approach in Mandibular Subcondyle Fractures. *Pakistan Journal of Health Sciences*, 4(01). <https://doi.org/10.54393/pjhs.v4i01.445>

*Corresponding Author:

Ali Raza
 Department of Health, Government of Sindh,
 Pakistan
ali.raza558@msn.com

Received Date: 15th December, 2022Acceptance Date: 28th January, 2023Published Date: 31st January, 2023

ABSTRACT

Mandibular condylar fracturing are a common outcome of mandibular trauma. Condylar and subcondylar injuries benefit best from the retromandibular technique, which also offers the greatest exposure to the joint and ascending ramus. **Objective:** To determine the efficacy of the retromandibular approach in treating condylar fractures with open reduction and internal fixation (ORIF). **Methods:** A total of 25 subjects with age range 14 to 55 years having unilateral mandibular condylar fractures with disturbed occlusion utilizing retromandibular approach were included in the study. Relevant information was gathered and evaluated. **Results:** The average age of the sufferer was 31.18 ± 8.17 years and mean duration of fracture was 5.32 ± 0.73 days. There were 21(84%) male patients and 04 (16%) female sufferers. RTA was the most common mode of injury seen among patients (60%). The shattered segments' anatomic reduction and fixation were successful. The efficacy was 72% on basis of ease of operation and 96% on fracture stability. **Conclusion:** This technique is effective in term of ease of operation and fracture stability. Scar acceptability can be considered drawback of this procedure.

INTRODUCTION

Mandibular condyle fractures account for 25% to 30% of all mandibular fractures, making it one of the most frequent facial fractures. Anywhere along the line from the sigmoid notch to the mandibular angle, there are many types of fractures that might happen. Various mandibular fractures are frequently present along with it [1]. The stabilization of fractures of the mandibular condyle head, neck, and base has long been a contentious issue. Many people hold the concept that essentially all displaced condylar fractures

should be repaired surgically, whereas others hold the opposite viewpoint [2]. These fractures are typically treated conservatively due to the technical challenges of exposing and fixing as well as the possibility of facial nerve damage. The incidence of delayed consequences including temporomandibular joint ankylosis, condylar necrosis, regression of mandibular development, and occlusal anomalies have been recorded in the research, despite the fact that favorable early clinical findings are frequently

obtained with conservative management [3]. Open surgery, as opposed to conservative treatment, can quickly restore normal occlusion and jaw movement. Condylar fractures have been treated surgically using a variety of techniques, including submandibular, preauricular, rhytidectomy, intraoral, and retromandibular. For subcondylar fractures, the submandibular approach has a very poor success rate, while the preauricular technique has a very high success rate. The retromandibular method is mentioned in the research as a possible option relatively occasionally [4]. Hinds and Girotti first suggested the retromandibular incision in 1967 [5]. It is chosen by surgeons because it offers clear visibility of the whole ramus and the lower subcondyle from the posterior edge [6]. This incision is closer to the subcondyle than the submandibular incision, allowing for easier fracture care and direct accessibility to the subcondyle's fractured line, which facilitates the subcondyle's reduction. Additionally, it enables the operator to operate perpendicular to the fracture, preventing the need for a transfacialtrochar and minimizing excessive retraction [7]. Additionally, it can prevent direct contact with the facial nerve, protect the function of the parotid gland and its capsule, and create a scarcely perceptible scar at a location that is largely covered. Mandibular subcondylar fractures are identified by a fracture line that is lower than the level of the sigmoid notch's most inferior portion [8]. In this study, open reduction and internal reduction for mandibular subcondylar fractures using the retromandibular technique were evaluated for effectiveness and results.

METHODS

The department of Oral and Maxillofacial Surgery, Institute of Dentistry, LUMHS Jamshoro, conducted this prospective non-controlled trial (case study) using non probability consecutive sampling from October 2021 to August 2022. The sample size calculation was done using the Raosoft Sample size calculating formula. With confidential interval 95%, power 90% and drop-out 10%, sample size became 25. Patients with age span of 18 to 50 years with clinical and radiographic evidence of unilateral displaced subcondylar fracture with disturbed occlusion, which are indicated for ORIF, were included in the study. Patients having bilateral subcondylar and condylar neck fractures, who were unwilling to take part in the trial, mentally retarded patients or those whose health makes them unfit for general anesthesia were excluded from study. This research comprised patients who met the inclusion requirements and were referred to the Outpatient Department (OPD) or the Emergency Department (ED). Every participant or their attendant signed a documented permission form. On the Proforma, participant information

such as name, age, gender, and hospital registration number were entered. After receiving clearance from the Ethical Review Committee, the study was carried out. Clinical assessment, orthopantomography (OPG), and P.A view of face were used to diagnose a mandibular condyle fracture. A written informed consent was taken before starting the surgical procedure. Mode of injury and duration of fracture were also noted. Open reduction and internal fixation with miniplates were performed on all patients using a retromandibular incision. The patient was recommended to go to the hospital and was maintained nil per oral for 6 hours the day before procedure. The general anesthesia permission was collected simultaneously on the day of operation by hospital staff. Before beginning surgery, the normal universal method for draping and preparation was followed. Procedure was carried out with lidocaine 2% with adrenaline 1:80000 (max: 7.5 mg/ml) at the incision site. The anticipated two-centimeter incision was made at the beginning of the procedure, around 0.5 cm inferior to the ear lobe and 0.5 cm posterior to the mandibular boundary. The course of the facial nerve branches was located using a nerve stimulator after passing the cutaneous, subcutaneous, and parotid capsules. A blunt dissection was then carried out from both sides of the nerve tract using a curving hemostat to expose the masseter muscle. After the pterygomasseteric sling was incised, the fracture line was forced by subperiosteal dissection using a periosteal elevator. After achieving anatomic reduction, two 2-mm titanium miniplates were used to stabilize the fracture line. Closure was done with resorbable suture followed by proline 3.0. All participants received intermaxillary training elastics for a week following surgery. Post operatively, patients were called for follow checkup at 3 months. After surgery, the patient's perception of the scar (acceptable to patient or not), facial nerve function (with nerve stimulator), fracture stability (by radiographic evaluation; no gap and proper ongoing healing), and occlusal disparity (lack of maximum intercuspation) were all evaluated. The procedure was labeled effective if the proper access to subcondylar area to reduce the fracture (ease of operation) and bone osteosynthesis with miniplates (fracture stability) and with no injury the facial nerve. Data analysis were performed in R programming. Age and duration of fracture were computed as mean and SD. Categorical data like gender, injury mechanism, and postoperative assessment calculated as frequencies and percentages. The effectiveness (ease of operation and fracture stability) was stratified among genders to see effect modification using Fisher exact test. $p < 0.05$ was taken significant threshold.

RESULTS

A total 25 patients with unilateral subcondylar fracture were treated with retromandibular incision. The mean age of the subjects was 31.18 ± 8.17 years and mean duration of fracture was 5.32 ± 0.73 days. The range for age and duration of fracture were 14–55 years and 3–7 days. There were 21(84%) male patients and 04(16%) females. The most common age group was 31–45 years ($n=14, 56\%$) followed by 15–30 years ($n=10, 40\%$) (Table 1).

Variable	Characteristic	N = 25*
Gender	Female	4(16.00)
	Male	21(84.00)
Age group (years)	15–30	10(40.00)
	31–45	14(56.00)
	45 and above	1(4.00)

Table 1: Distribution of gender and age group

*n(%)

RTA was the most common mode of injury seen among patients (60%), followed by fall (32%). One patient each was having sports injury and interpersonal violence. Details of mode of injury are mentioned in figure 1.

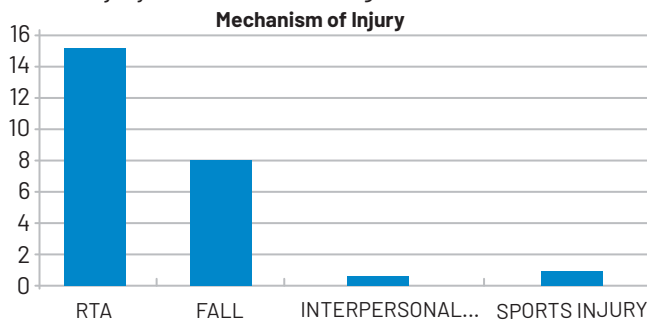


Figure 1: Showing mechanism of injury

Effectiveness on basis of ease of operation was 80% and on basis of fracture stability was 96%. Ease of operation was noted in 20(80%), fracture stability in 24(96%), 1 patient has postoperative facial nerve paresthesia, salivary fistula was noted in 3(12%). 18(72%) patients were satisfied with scar appearance. Only 1 patient was reported with malocclusion on one month follow up. All these findings are mentioned in table 2.

Variable	Characteristic	n (%)
Ease of Operation	Absent	5(20.00)
	Present	20(80.00)
Facial Nerve Injury	Absent	24(96.00)
	Present	1(4.00)
Salivary fistula	Absent	22(88.00)
	Present	3(12.00)
Scar Acceptability	Absent	7(28.00)
	Present	18(72.00)
Fracture Stability	Absent	1(4.00)
	Present	24(96.00)
Occlusal Discrepancy	Absent	24(96.00)
	Present	1(4.00)

Table 2: Outcomes of retromandibular approach at three months follow ups

The concern for scar among females was 50% and males were 23.81% but the difference was statistically significant. Similarly, the ease of operation and fracture stability was also not differed statistically ($p>0.99$) (Table 3).

Variable	Characteristic	Female, N = 4	Male, N = 21	p-value*
Ease of Operation	Absent	1(25.00)	4(19.05)	>0.999
	Present	3(75.00)	17(80.95)	
Scar Acceptability	Absent	2(50.00)	5(23.81)	0.644
	Present	2(50.00)	16(76.19)	
Fracture Stability	Absent	0(0.00)	1(4.76)	>0.999
	Present	4(100.00)	20(95.24)	

Table 3: Comparison of outcomes of retromandibular approach among genders

*Fisher exact test

DISCUSSION

Both conservative and surgical approaches can be used to treat subcondylar fractures. The conservative approach to treating condylar fractures was preferred in the past. However, an open reduction was the first treatment method used to stabilize a low subcondylar fracture in 1925, and it has subsequently become increasingly popular, most likely due to the development of plate and screw fixation systems [9]. Many surgeons today choose open reduction for displaced fractures because the stiff fixation and reduction allow for quick function and appropriate anatomic realignment [3]. In this study, open reduction and internal reduction for mandibular subcondylar fractures using the retromandibular technique were evaluated for effectiveness and outcomes. Our study comprised total 25 patients with unilateral subcondylar fracture, which were treated with retromandibular incision. The mean age of the subjects was 31.18 ± 8.17 years and mean fracture duration was 5.32 ± 0.73 days. There were 21(84%) male patients and 04(16%) female sufferers. RTA was most common mode of injury encountered in patients in this study. in around 76%. We feel ease in operation using this approach, and 96% patients were treated adequately and achieved stable occlusion. This approach provides better outcomes in terms of facial nerve injury and scar acceptability. Rahim et al., and Kshirsagar et al., findings, which claimed that the retromandibular technique gives a sufficient exposure for the majority of condylar fractures, offer strong justification for all of the research results of our work [10, 11]. Ellis and Dean evaluated the anatomy and several surgical techniques for addressing mandibular condyle fracture with plate and screws [12]. He discussed the benefits and drawbacks of the retromandibular approach, as well as the preauricular, submandibular, intraoral, and rhytidectomy techniques. He came to the conclusion that the

retromandibular technique is superior to the others because it has a shortened operating contact from the incision to the condyle, wider exposure because the tissue can be retracted up to the extent of the sigmoid notch, outstanding visibility even in faces with marked edema. The majority of condylar fractures can be successfully exposed via the retromandibular technique. The material of the parotid gland may contain branches of the facial nerve and retromandibular vein. As the technique crosses the gland, there is a potential of a salivary fistula, which can be avoided by transfixing the gland capsule. The majority of fistulas heal on their own [13]. In this study 3 patients were found to have salivary fistula, which is somewhat not desired by the surgeon. In our viewpoint, failing to restore the parotid capsule will probably lead to a salivary fistula. Ayub et al., in their study similar to our findings have noticed 1 case of salivary fistula while utilizing retromandibular approach [14]. In this study, only 1 patient out of 25 experienced some occlusal discrepancy following the procedure. The fracture line can be reached at a straight angle using the retromandibular approach, and the force applied to the fractured edge is readily visible. The fixation of the fracture anatomically is facilitated, according to the experts. Facial nerve was noted in one patient in this study, which was temporary and resolved afterwards. The likelihood of facial nerve injury increases with strong soft tissue retraction and ranges from 30 to 48% [15, 16]. According to different research, the likelihood of facial nerve damage after surgical fracture repair of the mandibular condyle varies from 12% to 48% [17,18]. Dissection and retraction of the tissue, handling of fracture pieces, or the use of hardware may all cause nerve injury [19, 20]. To treat subcondylar and high ramus mandibular fractures with extraoral surgery, we think the retromandibular approach is the best option because it provides effortless access to the fracture line, ensures that the scar is hidden behind the mandible for aesthetic reasons, and has a relatively little complications frequency.

CONCLUSIONS

Our observations of 25 patients indicated that the retromandibular route was a secure and efficient technique. The subcondylar region is adequately exposed using the retromandibular technique, which is a respectable alternative in the treatment of condylar fractures.

Conflicts of Interest

The authors declare no conflict of interest

Source of Funding

The authors received no financial support for the research, authorship and/or publication of this article

REFERENCES

- [1] Samson J, S H, Balasubramanian A, Jayabalan J. Retromandibular Approach for Mandibular Sub Condylar Fracture: A Review of Literature. *Acta Scientific Dental Sciencs*. 2021 Aug; 5(9): 11-20. doi: 10.31080/asds.2021.05.1180
- [2] Bhat SV, Krishna VK, Periasamy S, Kumar SP, Krishnan M. Modified Retromandibular Approach for the Management of Condylar Fractures of the Mandible. *Cureus*. 2022 Aug; 14(8): e27697. doi: 10.7759/cureus.27697
- [3] Lee HC, Kang DH, Koo SH, Park SH. Outcome of open reduction via retromandibular approach for mandibular subcondyle fracture. *Archives of Plastic Surgery*. 2005Nov; 32(6): 739-43.
- [4] EJ VS, Perales R, VC PL. Retromandibular approach for subcondylar fractures. *Acta Otorrinolaringologica Espanola*. 2006 Apr; 57(4): 186-8. doi: 10.1016/S0001-6519(06)78689-7
- [5] Hinds EC and Girotti WJ. Vertical subcondylar osteotomy: a reappraisal. *Oral Surgery, Oral Medicine, Oral Pathology*. 1967 Aug; 24(2): 164-70. doi: 10.1016/0030-4220(67)90256-3
- [6] Kang DH. Surgical management of a mandible subcondylar fracture. *Archives of Plastic Surgery*. 2012 Jul; 39(04): 284-90. doi: 10.5999/aps.2012.39.4.284
- [7] JANG JY and KANG DH. Comparison study of open reduction and closed reduction in treatment of mandibular subcondylar fractures. *Journal of the Korean Cleft Palate-Craniofacial Association*. 2008:51-4.
- [8] Ellis III E. Method to determine when open treatment of condylar process fractures is not necessary. *Journal of Oral and Maxillofacial Surgery*. 2009 Aug; 67(8): 1685-90. doi: 10.1016/j.joms.2009.03.062
- [9] Silverman SL. A new operation for displaced fractures at the neck of the mandibular condyle. *Dental Cosmos*. 1925 Sep; 67: 876-7.
- [10] Rahim A ur, Ali S, Nauman M, Qayyum T, Khan A, Abdullah Khan M, et al. Comparison of Preauricular Approach Versus Retromandibular Approach in Management of Condylar Fractures. *Pakistan Journal of Medical and Health Sciences*. 2021 Aug; 15(8): 2137-40. doi: 10.53350/pjmhs211582137
- [11] Kshirsagar R, Singh V, Pawar S, Shah R. Retromandibular approach in the management of condylar fractures by open reduction and internal fixation a prospective study. *National Journal of Maxillofacial Surgery*. 2015 Jul; 6(2): 180-4. doi: 10.4103/0975-5950.183852
- [12] Ellis III E and Dean J. Rigid fixation of mandibular

- condyle fractures. *Oral Surgery, Oral Medicine, oral Pathology*. 1993 Jul; 76(1): 6-15. doi: 10.1016/0030-4220(93)90285-C
- [13] Narayanan VI, Kannan R, Sreekumar K. Retromandibular approach for reduction and fixation of mandibular condylar fractures: a clinical experience. *International Journal of Oral and Maxillofacial Surgery*. 2009 Aug; 38(8): 835-9. doi: 10.1016/j.ijom.2009.04.008
- [14] Ayub T, Kumari B, Kumar R, Abro B, Hassan SG, Shams S. Comparison of Preauricular Versus Retromandibular Approach in the Management of Mandibular Condyle Fractures. *Journal of Pharmaceutical Research International*. 2022 Jan; 34(2A): 28-35. doi: 10.9734/jpri/2022/v34i2A35357
- [15] Kempers KG, Quinn PD, Silverstein K. Surgical approaches to mandibular condylar fractures: a review. *The Journal of Cranio-Maxillofacial Trauma*. 1999 Jan; 5(4): 25-30.
- [16] Choi BH and Yoo JH. Open reduction of condylar neck fractures with exposure of the facial nerve. *Oral Surgery, Oral Medicine, Oral Pathology, Oral Radiology, and Endodontology*. 1999 Sep; 88(3): 292-6. doi: 10.1016/S1079-2104(99)70030-2
- [17] Downie JJ, Devlin MF, Carton AT, Hislop WS. Prospective study of morbidity associated with open reduction and internal fixation of the fractured condyle by the transparotid approach. *British Journal of Oral and Maxillofacial Surgery*. 2009 Jul; 47(5): 370-3. doi: 10.1016/j.bjoms.2008.11.002
- [18] Yang L and Patil PM. The retromandibular transparotid approach to mandibular subcondylar fractures. *International Journal of Oral and Maxillofacial Surgery*. 2012 Apr; 41(4): 494-9. doi: 10.1016/j.ijom.2011.09.023
- [19] Yamamoto MK, D'Avila RP, de Cerqueira Luz JG. Evaluation of surgical retreatment of mandibular fractures. *Journal of Cranio-Maxillofacial Surgery*. 2013 Jan; 41(1): 42-6. doi: 10.1016/j.jcms.2012.05.008
- [20] EJ VS, Perales R, VC PL. Retromandibular approach for subcondylar fractures. *Acta Otorrinolaringologica Espanola*. 2006 Apr; 57(4): 186-8. doi: 10.1016/S0001-6519(06)78689-7