



Original Article

Frequency of Uterine Leiomyomas in Multipara Women

Fatima Latif¹, Akash John¹, Abid Ali¹, Rehan Afsar¹, Iqra Ashfaq¹¹Department of Allied Health Sciences, University Institute of Radiological Sciences and Medical Imaging, The University of Chenab, Gujrat, Pakistan.

ARTICLE INFO

Key Words:

Uterine Fibroids, Leiomyomas, Frequency, Sonography, Multipara

How to Cite:

Latif, F. ., John, A. ., Ali, A. ., Afsar, R. ., & Ashfaq, I. . (2022). Frequency of Uterine Leiomyomas in Multipara Women: Frequency of Uterine Leiomyomas in Multipara Women. *Pakistan Journal of Health Sciences*, 3(01).
<https://doi.org/10.54393/pjhs.v3i01.55>

***Corresponding Author:**

Fatima Latif
 The University of Chenab, Gujrat, Pakistan
fatima.latif56@gmail.com

Received Date: 28th May, 2022
 Acceptance Date: 14th June, 2022
 Published Date: 30th June, 2022

ABSTRACT

Fibroids are typically well-defined solid masses that have a convoluted appearance. These are generally echogenic like the myometrium, though sometimes they can indeed be hypoechoic. **Objective:** To determine the incidence of uterine leiomyomas in multipara women in Gujranwala, Pakistan. **Methods:** A cross-sectional study was conducted at the diagnostic department of radiology (DHQ/Teaching Hospital, Gujranwala). The study lasted for three months, from February 24, 2022, to May 24, 2022. A total of 140 people participated in the research after written informed consent. 140 multiparous women with uterine fibroids were included between the mentioned dates. The examination of the patients included pelvic ultrasonography with a full bladder. **Results:** This survey consisted of 140 multiparous women. 100 (64.1%) of 140 females having fibroid uterus who reported to the gynaecology department exhibited submucosal fibroids, 33 (21.2%) contained intramural fibroids, and 23 (14.7%) of them had subserosal fibroids. Fibroids with 127 (81.4%) in the anterior and 29 (18.6%) in the posterior were observed. Menstrual inconsistency was the most prevalent clinical presentation of reported cases, featuring menorrhagia in 105 (75%) patients, polymenorrhagia in 24 (17.1%) patients, and abdominal discomfort in 44 (31.4%) patients, and urinary frequency in 29 (27.9%) women. A total of 47 (33.6%) of the females had a family background of uterine fibroids. **Conclusion:** Submucosal fibroids are the most abundant, followed by intramural and subserosal fibroids, with pedunculated fibroids being the least frequent. The anterior part of the uterus is the most probable site of fibroid emergence. Menorrhagia was the most prevalent symptom.

INTRODUCTION

The uterus is a berry-shaped organ constituted of a fundus, body, isthmus, and cervix [1], each superolateral inclination has a fallopian tube that penetrates above the fundus [2]. Uterine fibroids (UFs) are innocuous smooth muscle growths of the uterus that primarily impact women of reproductive age [3]. They are observed to arise in around 70% of women by the time they hit menopause [4]. Even though the pathogenesis of fibroids is uncertain, there is compelling proof that oestrogens and progesterone stimulate tumour development [5], as leiomyoma seldom develop before menarche and dissipate afterwards menopause [6]. They might be a solitary nodules or a cluster of nodules, and their dimension can range from minute sprouts to colossal masses [7]. They can lead to severe complications, such as substantial or protracted

menstrual flow, pelvic strain or pain, and, in exceptional instances, reproductive problems [8]. Irregular bleeding, pelvic lumps, pelvic irritation, infertility, bulk symptoms, and maternity problems are among some of the clinical manifestations [9]. Fibroids are linked with an increased incidence of the black race, hereditary factors, parity, obesity, polycystic ovary disease [10], and there is preliminary proof that genetic tendency to fibroids is attributed to a specific specimen of clinical features when contrasted to leiomyoma not having genetic predominance [11]. Subserosal (sticking outside the uterus), intramural (inside the myometrium), submucosal (projecting into the uterine cavity), and pedunculated fibroids (fibroids that are attached to the uterus wall by a stalk) are the different types of uterine fibroids based on

their location [12]. The determination of fibroids is conventionally built on observing a dilated, mobile uterus comprising erratic pattern on bimanual assessment or an unintended finding on trans-abdominal sonography [13]. Preoperatively, radiological scanning manners can help support the diagnosis or enhance the localization of a myoma [14]. Ultrasonography is the standard scanning tool for the evaluation of uterine fibroids [15]. Ultrasound should be used foremost because ultrasonography is the least presumptuous and economical inquisition [16]. Abdominal ultrasonography is undertaken with the bladder filled enough to establish a "window" [17]. For the sake of the patient's convenience, vaginal ultrasound studies are conducted with an empty bladder [18]. Depending on the attributes of the growth, uterine fibroids might appear in a range of ways on ultrasound [19]. Fibroids are typically well-defined solid masses that have a convoluted appearance. These are generally echogenic like the myometrium, though sometimes they can indeed be hypoechoic [20]. They might render the uterus appear thick or disrupt the ordinary uterine structure [21]. Although fibroids that aren't cemented could have a proportion of posterior acoustic shadowing [22]. Priorly, uterine leiomyomas were seen as fundamental, particularly as the primary culprit of hysterectomy [23]. The management of uterine leiomyomas can be accomplished in several ways. Operative techniques include hysterectomy, myomectomy, myolysis, MR-guided focused ultrasound surgery, and uterine artery embolization, as well as medicinal alternatives including hormonal therapy and gonadotropin-releasing hormone agonists [24]. Uterine fibroids (UF) are a major health concern that impose a significant monetary impact, with Africans holding the greatest prevalence worldwide [25]. As per the research, methodologically, prevalence estimates in a recent analysis varies from 4.5 to 68.6% [26]. This research will guide us to assess the prevalence of uterine fibroids in multipara women as well as to define where they most likely develop.

METHODS

A cross-sectional study with a sample size of 140 patients [14] having uterine fibroids was undertaken using a purposive sampling technique. This survey was carried out on patients who came to the Gynaecology Department of the DHQ/Teaching Hospital in Gujranwala after written informed consent. The survey was performed for three months, from February 24th to May 24th, 2022. All patients who reported to the gynaecology department with a uterine fibroid and a parity of three or more were included in the research work. Women not having perceptible pelvic growths associated with periodic irregularity, parity less

than three, mass other than uterine fibroid, and ultrasonography-diagnosed ovarian mass were omitted. The pelvic examination was performed using ultrasound machine (Toshiba, Aplio 300) with a curvilinear probe with frequency range of 2-5MHz. IBM SPSS version 26.0 was used to analyse data.

RESULTS

The ages of the patients were ranging from 23 to 60 years old. This research consisted of 140 multiparous women. Table 1 shows that 100 (64.1%) of 140 females with fibroid uterus who reported to the gynaecology department had submucosal fibroids, 33 (21.2%) had intramural fibroids, and 23 (14.7%) had subserosal fibroids.

Type of Fibroid	Frequency	Percent
Submucosal	100	64.1
Subserosal	23	14.7
Intramural	33	21.2
Total	156	100.0

Table 1: Frequency of Uterine Fibroids based on Their Type

Both anterior and posterior regions of the uterus, with 127 (81.4%) in the anterior and 29 (18.6%) in the posterior.

Location of Fibroid	Frequency	Percent
Anterior	127	81.4
Posterior	29	18.6
Total	156	100.0

Table 2: Frequency of Uterine Fibroids based on Their Location

Table 2 demonstrate that fibroids were observed within Table 3 exhibit that the most common reporting problem of patients with uterine leiomyoma in this investigation was menorrhagia in 105 (75%) patients followed by abdominal pain in 44 (31.4%) patients, urinary frequency in 39 (27.9%), and polymenorrhagia in 24 (17.1%) patients.

Presenting Complain	Frequency	Percent
Menorrhagia	105	75
Polymenorrhagia	24	17
Abdominal Pain	44	31.4
Urinary Frequency	39	27.9

Table 3: Frequency of Presenting Complaints of Patients

Figure 1 showcase that a total of 47 (33.6%) of the females had a family history associated with uterine fibroids.

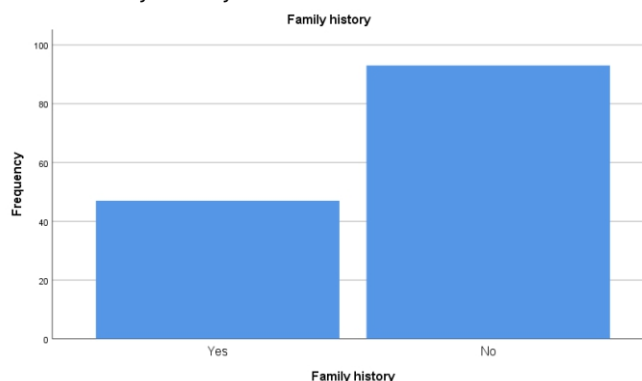


Figure 1: Association of family history with uterine fibroids

DISCUSSION

It was a cross-sectional study with a sample size of 140 patients having uterine fibroids and was carried out on patients who came to the Gynaecology Department of the DHQ/Teaching Hospital in Gujranwala. The survey was performed for three months, from February 24th to May 24th, 2022. All patients who reported to the gynaecology department with a uterine fibroid and a parity of three or more were included in the research work. Women not having perceptible pelvic growths associated with periodic irregularity, parity lesser than three, mass other than uterine fibroid, and ultrasonography-diagnosed ovarian mass were omitted. In present study, 100 (64.1%) of 140 females with fibroid uterus who reported to the gynaecology department had submucosal fibroids, 33 (21.2%) had intramural fibroids, and 23 (14.7%) had subserosal fibroids. Okogbo et al. also stated the same results in their research [27]. The definitive diagnosis of leiomyoma was established based on clinical findings and USGs conducted on all participants in our research. According to Gambone et al., based on the clinical findings, the diagnosis of uterine fibroids can be achieved with around 95% certainty [28]. As per Abraham et al. research, myoma diagnosis is heavily reliant on clinical manifestations, but USG can help validate that the tumours aren't extraneous uterine masses [29]. In current research, the most common reporting problem of patients with uterine leiomyoma was menorrhagia in 105 (75%) patients followed by abdominal pain in 44 (31.4%) patients, urinary frequency in 39 (27.9%), and polymenorrhagia in 24 (17.1%) patients. Considering menorrhagia concerns 9% to 14% of healthy women, many health providers will see patients experiencing menorrhagia-related complications. Uterine fibroids, adenomyosis, DUB, pelvic infection, endometrial polyp, as well as the existence of a foreign body, such as an intrauterine contraceptive device, are believed to be linked to menorrhagia. As per current data, uterine leiomyomas, which probably grow in usually more than 50% of women, are innocuous but can induce several conditions and difficulties. They may, for instance, cause anomalous uterine bleeding, concealing the detection of ovarian tumours and perplexing the administration of menopause. The patients in this analysis were multiparous with parity of three or more. As fibroids are oestrogen-dependent, their aging value is generally from menarche to menopause. They progress slowly and seldom lead to complications until the third decade of life. During this examination, it was determined that multiparous women who were later described with fibroid uterus exhibited a multitude of menstruation issues as well as lower abdominal swelling,

which patients misinterpreted as gaining weight after labour. Menstrual problems prompted them to report to the hospital and have themselves examined. In current study, fibroids were observed within both anterior and posterior regions of the uterus, with 127 (81.4%) in the anterior and 29 (18.6%) in the posterior as stated by Zhang et al, in their study published in 2010 [30]. Another study conducted by JChen et al, published in 2015 also concluded similar results that 3496 fibroids were found in the anterior wall (47.0%) and 2306 in the posterior wall (31.0%) [31]. Present study shows that a total of 47 (33.6%) of the females had a family history associated with uterine fibroids as concluded by Stewart et al. study published in 2017 [4]. A research conducted by Ciebiera et al, published in 2016 also showed that positive family history has direct influence in fibroid development [32].

CONCLUSION

The most frequent fibroids seen in patients were submucosal fibroids, trailed by intramural fibroids, and then subserosal fibroids, no pedunculated fibroids were recorded throughout the observation period. Menorrhagia was the most prevalent clinical complaint amongst women with fibroid uterus.

REFERENCES

- [1] Wynn R, editor. *Biology of the uterus*. Springer Science & Business Media; 2013 Jun.
- [2] Ellis H. *Anatomy of the uterus*. *Anaesthesia & Intensive Care Medicine*. 2011 Mar; 12(3):99-101. doi: 10.1016/j.mpaic.2010.11.005.
- [3] Wray S. *Insights into the uterus*. *Experimental Physiology*. 2007 Jul; 92(4):621-31. doi: 10.1113/expphysiol.2007.038125
- [4] Stewart EA, Cookson CL, Gandolfo RA, Schulze-Rath R. *Epidemiology of uterine fibroids: a systematic review*. *BJOG: An International Journal of Obstetrics & Gynaecology*. 2017 Sep; 124(10):1501-1512. doi: 10.1111/1471-0528.14640.
- [5] Asada H, Yamagata Y, Taketani T, Matsuoka A, Tamura H, Hattori N, et al. *Potential link between estrogen receptor-alpha gene hypomethylation and uterine fibroid formation*. *Molecular human reproduction*. 2008 Sep; 14(9):539-45. doi: 10.1093/molehr/gan045.
- [6] Khan AT, Shehmar M, Gupta JK. *Uterine fibroids: current perspectives*. *International Journal of Women's Health*. 2014 Jan; 6:95-114. doi: 10.2147/IJWH.S51083.
- [7] Ciavattini A, Clemente N, Delli Carpini G, Di Giuseppe J, Giannubilo SR, Tranquilli AL. *Number and size of uterine fibroids and obstetric outcomes*. *Journal of Maternal, Fetal, and Neonatal Medicine*. 2015 Mar; 28(4):484-8. doi: 10.3109/14767058.2014.921675.

- [8] Stewart EA. Uterine fibroids. *Lancet*. 2001 Jan ; 357(9252):293-8. doi:10.1016/S0140-6736(00)03622-9.
- [9] Donnez J, Dolmans MM. Uterine fibroid management: from the present to the future. *Human Reproduction Update*. 2016 Nov; 22(6):665-686. doi: 10.1093/humupd/dmw023.
- [10] Lethaby A, Vollenhoven B. Fibroids (uterine myomatosis, leiomyomas). *American Family Physician*. 2005 May; 71(9):1753.
- [11] Gross KL, Morton CC. Genetics and the development of fibroids. *Clinical Obstetrics and Gynaecology*. 2001 Jun; 44(2):335-49. doi: 10.1097/00003081-20010600-00020
- [12] De La Cruz MS, Buchanan EM. Uterine Fibroids: Diagnosis and Treatment. *American Family Physician*. 2017 Jan; 95(2):100-107.
- [13] Stoelinga B, Huirne J, Heymans MW, Reekers JA, Ankum WM, Hehenkamp WJ. The estimated volume of the fibroid uterus: a comparison of ultrasound and bimanual examination versus volume at MRI or hysterectomy. *European Journal of Obstetrics & Gynecology and Reproductive Biology*. 2015 Jan; 184:89-96. doi:10.1016/j.ejogrb.2014.11.011.
- [14] Ibrar F, Riaz S, Dawood NS, Jabeen A. Frequency of fibroid uterus in multipara women in a tertiary care centre in Rawalpindi. *ournal of Ayub Medical College Abbottabad*. 2010 Sep; 22(3):155-7.
- [15] Deveer M, Deveer R, Engin-Ustun Y, Sarikaya E, Akbaba E, Senturk B, et al. Comparison of pregnancy outcomes in different localizations of uterine fibroids. *Clinical and experimental obstetrics & gynecology*. 2012 Dec; 39(4):516-8.
- [16] Evans P, Brunzell S. Uterine fibroid tumors: diagnosis and treatment. *American family physician*. 2007 May; 75(10):1503-8.
- [17] Tranquart F, Brunereau L, Cottier JP, Marret H, Gallas S, Lebrun JL, et al. Prospective sonographic assessment of uterine artery embolization for the treatment of fibroids. *Ultrasound in Obstetrics and Gynaecology*. 2002 Jan; 19(1):81-7. doi: 10.1046/j.0960-7692.2001.00535.x
- [18] Hurst BS. Uterine fibroids. In *Ultrasound imaging in reproductive medicine*. Springer, Cham. 2019: 137-53.
- [19] Benaglia L, Cardellicchio L, Filippi F, Paffoni A, Vercellini P, Somigliana E, Fedele L. The rapid growth of fibroids during early pregnancy. *PLoS One*. 2014 Jan; 9(1):e85933. doi: 10.1371/journal.pone.
- [20] Capezzuoli T, Vannuccini S, Fantappiè G, Orlandi G, Rizzello F, Coccia ME, Petraglia F. Ultrasound findings in infertile women with endometriosis: evidence of concomitant uterine disorders. *Gynaecological Endocrinology*. 2020 Sep; 36(9):808-812. doi: 10.1080/09513590.2020.1736027.
- [21] Bulun SE. Uterine fibroids. *New England Journal of Medicine*. 2013 Oct; 369(14):1344-55. doi: 10.1056/NEJMra1209993.
- [22] Wilde S, Scott-Barrett S. Radiological appearances of uterine fibroids. *Indian Journal of Radiology and Imaging*. 2009 Sep; 19(3):222-31. doi: 10.4103/0971-3026.54887.
- [23] Walker CL, Stewart EA. Uterine fibroids: the elephant in the room. *Science*. 2005 Jun; 308(5728):1589-92. doi: 10.1126/science.1112063.
- [24] Levy BS. Modern management of uterine fibroids. *Acta obstetrica et gynecologica Scandinavica*. 2008; 87(8):812-23. doi:10.1080/00016340802146912.
- [25] Dvornyk V. Significant interpopulation differentiation at candidate loci may underlie ethnic disparities in the prevalence of uterine fibroids. *Journal of Genetics*. 2021;100:90.
- [26] Al-Hendy A, Myers ER, Stewart E. Uterine Fibroids: Burden and Unmet Medical Need. *Seminars in Reproductive Medicine*. 2017 Nov;35(6):473-480. doi: 10.1055/s-0037-1607264.
- [27] Okogbo FO, Ezechi OC, Loto OM, Ezeobi PM. Uterine Leiomyomata in South Western Nigeria: a clinical study of presentations and management outcome. *African Health Sciences*. 2011; 11(2).
- [28] Gambone JC, Reiter RC. Nonsurgical management of chronic pelvic pain: a multidisciplinary approach. *Clinical Obstetrics and Gynecology*. 1990 Mar; 33(1):205-11. DOI: [10.1097/00003081-199003000-00026](https://doi.org/10.1097/00003081-199003000-00026)
- [29] Abraham R. Uterine fibroids. In: *Manual of clinical problems in Obstet Gynaecol 4th(ed)*. 1994: 227-9.
- [30] Zhang L, Chen WZ, Liu YJ, Hu X, Zhou K, Chen L, Peng S, Zhu H, Zou HL, Bai J, Wang ZB. Feasibility of magnetic resonance imaging-guided high intensity focused ultrasound therapy for ablating uterine fibroids in patients with bowel lies anterior to uterus. *European journal of radiology*. 2010 Feb; 73(2):396-403. doi.org/10.1016/j.ejrad.2008.11.002
- [31] Chen J, Chen W, Zhang L, Li K, Peng S, He M, Hu L. Safety of ultrasound-guided ultrasound ablation for uterine fibroids and adenomyosis: a review of 9988 cases. *Ultrasonics sonochemistry*. 2015 Nov; 27:671-6. doi.org/10.1016/j.ultsonch.2015.05.031
- [32] Ciebiera M, Włodarczyk M, Słabuszewska-Józwiak A, Nowicka G, Jakiel G. Influence of vitamin D and transforming growth factor β 3 serum concentrations, obesity, and family history on the risk for uterine fibroids. *Fertility and Sterility*. 2016 Dec; 106(7):1787-92. doi.org/10.1016/j.fertnstert.2016.09.007